






BRIEF COMMUNICATION

Real-Time Magnetic Resonance Imaging to Study Orthostatic Intolerance Mechanisms in Human Beings: Proof of Concept

Darius A. Gerlach , PhD*; Andrea Maier , MD*; Jorge Manuel , PhD; Anja Bach; Alex Hoff , MSc; Jan-Niklas Hönemann , MD; Karsten Heusser , MD; Dirk Voit, PhD; Jens Frahm , PhD; Jens Jordan , MD*; Jens Tank , MD*

BACKGROUND: Discerning the mechanisms driving orthostatic symptoms in human beings remains challenging. Therefore, we developed a novel approach combining cardiac and cerebral real-time magnetic resonance imaging, beat-to-beat physiological monitoring, and orthostatic stress testing through lower-body negative pressure (LBNP). We conducted a proof-of-concept study in a patient with severe orthostatic hypotension.

METHODS AND RESULTS: We included a 46-year-old man with pure autonomic failure. Without and during -30 mmHg LBNP, we obtained 3T real-time magnetic resonance imaging of the cardiac short axis and quantitative flow measurements in the pulmonary trunk and middle cerebral artery. Blood pressure was 118/74 mmHg during supine rest and 58/35 mmHg with LBNP. With LBNP, left ventricular stroke volume decreased by 44.6%, absolute middle cerebral artery flow by 37.6%, and pulmonary trunk flow by 40%.

CONCLUSIONS: Combination of real-time magnetic resonance imaging, LBNP, and continuous blood pressure monitoring provides a promising new approach to study orthostatic intolerance mechanisms in human beings.

REGISTRATION: URL: <https://www.clinicaltrials.gov>; Unique Identifier: NCT04310644.

Key Words: hypotension, orthostatic intolerance ■ lower-body negative pressure ■ middle cerebral artery

Orthostatic intolerance, which encompasses orthostatic hypotension, postural tachycardia syndrome, and neurally mediated (vasovagal) syncope, may result from changes in systemic hemodynamics, altered cerebrovascular control, or both mechanisms combined. In a patient with low blood volume or cardiac deconditioning, systemic hemodynamics while standing may be maintained through increased heart rate, resulting in palpitations, shortness of breath, and exercise intolerance. Symptoms of cerebral hypoperfusion or overt syncope may occur when systemic blood pressure decreases below the autoregulatory range of the cerebral circulation or during

rapid blood pressure drops.¹ Cerebral vasoconstriction can also elicit orthostatic symptoms in the absence of critical systemic blood pressure reductions.² However, discerning mechanisms driving orthostatic symptoms in an individual patient, which could guide clinical management, remains difficult with current diagnostic modalities. We developed a novel approach combining cardiac and cerebral real-time magnetic resonance imaging (MRI),^{3,4} beat-to-beat physiological monitoring, and orthostatic stress testing through lower-body negative pressure (LBNP) (Figure 1A). We tested the approach in a patient with severe orthostatic hypotension caused by pure autonomic failure.

Correspondence to: Jens Tank, MD, German Aerospace Center (DLR), Institute for Aerospace Medicine, Linder Hoehe, Cologne, N/A 51147 Germany. Email: jens.tank@dlr.de

*D. A. Gerlach, A. Maier, J. Jordan, and J. Tank contributed equally.

For Sources of Funding and Disclosures, see page 4.

© 2022 The Authors. Published on behalf of the American Heart Association, Inc., by Wiley. This is an open access article under the terms of the [Creative Commons Attribution-NonCommercial](#) License, which permits use, distribution and reproduction in any medium, provided the original work is properly cited and is not used for commercial purposes.

JAHA is available at: www.ahajournals.org/journal/jaha

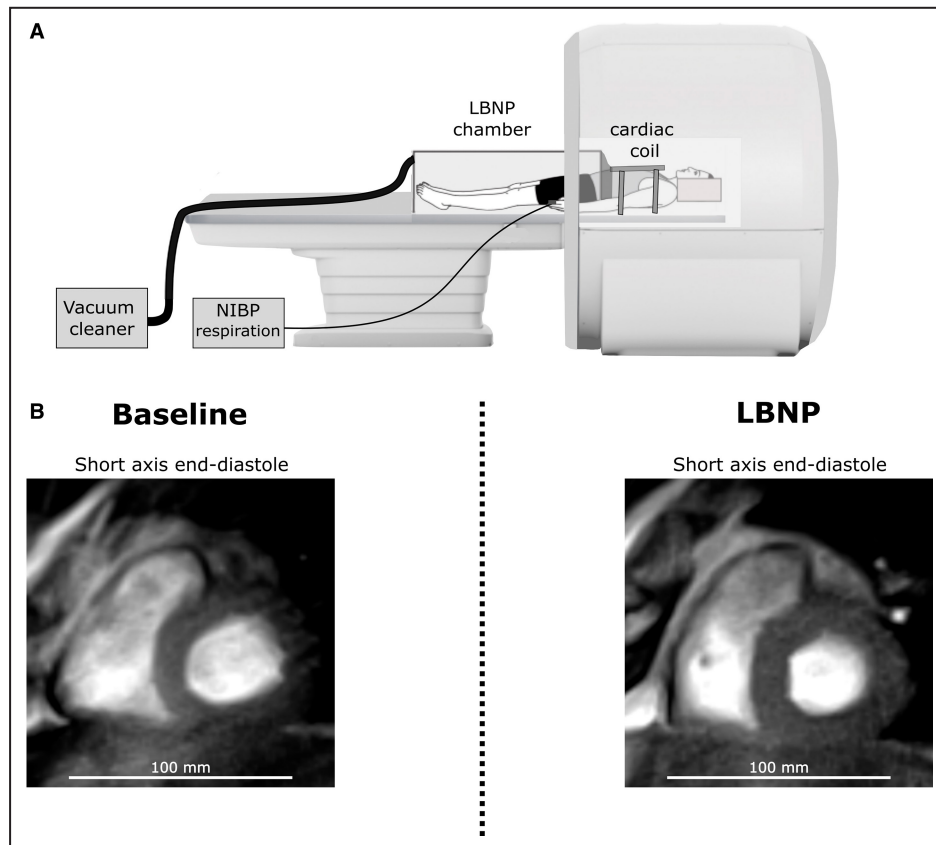


Figure 1. Real-time magnetic resonance imaging during orthostatic challenge in a human. **A**, Schematic drawing of the cardiac real-time magnetic resonance imaging (MRI) setup with lower-body negative pressure (LBNP) and physiological monitoring including ECG, noninvasive beat-to-beat blood pressure (NIBP), and respiration. **B**, Midventricular MRI short-axis view during diastole before (left) and during (right) LBNP. Blood filling is visually reduced during LBNP.

METHODS

Anonymized data and materials have been made publicly available at Zenodo and can be accessed at: <https://doi.org/10.5281/zenodo.7066641>. We studied a 46-year-old man with a 7-year history of orthostatic dizziness and syncope, bladder dysfunction, erectile dysfunction, and impaired night vision. Following recurrent orthostatic syncope resulting in injuries, he presented to the autonomic nervous system unit at Aachen University Hospital in 2020. Autonomic testing revealed severe orthostatic hypotension and cardiovascular, adrenergic, and sudomotor dysfunction. Supine and upright plasma norepinephrine concentrations were profoundly reduced. The study was approved by the North Rhine ethics committee and conducted according to the Declaration of Helsinki after obtaining written informed consent.

In a 3T scanner (Biograph mMR; Siemens), we recorded beat-to-beat finger blood pressure using a customized device (NOVA; Finapres Measurement Systems), ECG, and respiration. We have modified the finger blood pressure system for MRI through mu-metal

shielding of the electrical parts.⁵ We also applied longer than usual tubing between the finger cuff and the device to further limit magnetic field influences on the device.⁵ Furthermore, we applied an MRI-compatible LBNP chamber, which was sealed at the level of the iliac crest and fitted into the scanner bore (Figure 1A).

We used real-time MRI to obtain cardiac left short-axis slices with 300 images each at 33-ms time resolution without breath-holding (Figure 1B). We quantified pulmonary trunk blood flow for 30s, with 33-ms temporal and $1.5 \times 1.5 \times 6$ -mm³ spatial resolution. The measurement position was above the pulmonary valve and proximal to the pulmonary artery bifurcation. Furthermore, we measured the middle cerebral artery (MCA) for 32s, with 80-ms temporal and $0.75 \times 0.75 \times 6$ -mm³ spatial resolution with 100-cm/s velocity encoding. Positioning was according to previous studies.⁶ We obtained measurements after 20-minutes supine rest and during -30 -mmHg LBNP providing modest orthostatic stress.

Statistical Analysis

Data were analyzed with Cafur (Fraunhofer MEVIS).

RESULTS

Blood pressure was 118/74 mmHg at baseline and 58/35 mmHg during LBNP, which was associated with moderate symptoms. Despite the hypotension, heart rate only changed from 67 to 72 bpm (Figure 2A). At baseline, left ventricular end-systolic volume was 24±4 mL, end-diastolic volume was 98±5 mL, and ejection fraction was 76%. During LBNP, end-systolic volume was 26±4 mL, end-diastolic volume was 67±4 mL, and ejection fraction was 62%. Left ventricular stroke volume decreased from 74±6 mL at baseline to 41±6 mL during LBNP and cardiac output decreased from 4.96 L/min to 2.95 L/min, whereas systemic vascular resistance failed to increase. Pulmonary trunk blood flow decreased from 4.5±0.5 to 2.7±1.5 L/min with LBNP (Figure 2B). Respiration rate was 15.5±3.9 min⁻¹ without and 16.4±2.2 min⁻¹ with LBNP. Left MCA blood flow decreased from 0.17±0.01 L/min at baseline to 0.11±0.01 L/min during LBNP (Figure 2C), and

peak blood flow velocity decreased from 38.1±1.5 to 21.1±1.9 cm/s. Left MCA area increased with LBNP from 15.4±0.5 to 18.6±0.7 mm². The right MCA showed an overall qualitatively similar response with a reduction in blood flow from 0.1±0.01 L/min at baseline to 0.06±0.01 L/min during LBNP, peak blood flow velocity decreased from 31.4±1.4 to 18.7±2.2 cm/s, and artery area increased slightly from 7.1±0.5 to 7.5±0.4 mm². Assuming 70% brain tissue perfusion by the MCA, the brain volume measured 932.3 mL, and using a 1.04-g tissue factor, we arrived at a brain perfusion of 39.8 mL/min per 100 g at baseline and 25.0 mL/min per 100 g during LBNP.

DISCUSSION

Combination of real-time MRI, physiological profiling, and LBNP can be used to assess orthostatic intolerance mechanisms in patients. In our patient,

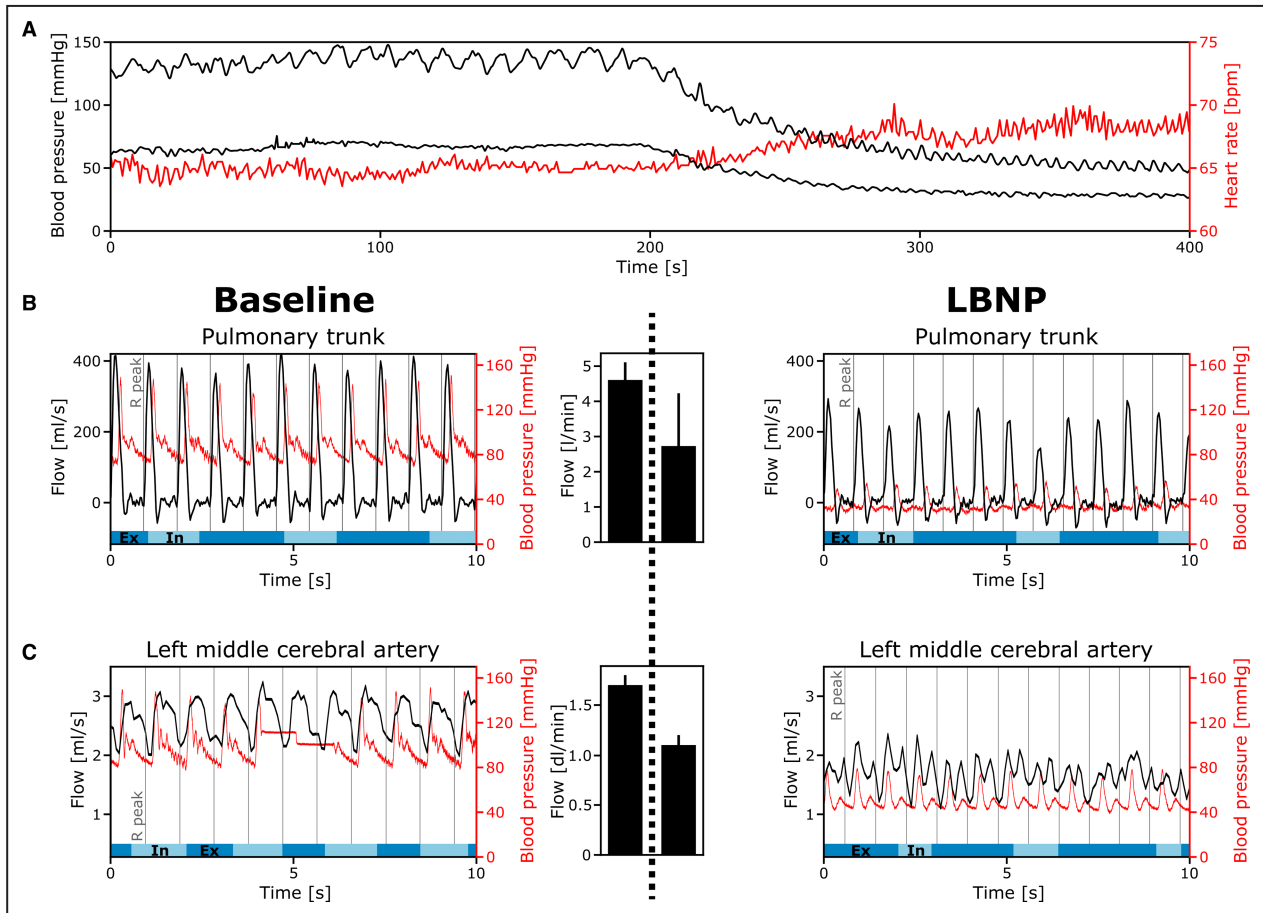


Figure 2. Cardiovascular and cerebrovascular reaction to lower-body negative pressure (LBNP).

A, Systolic blood pressure, diastolic blood pressure (black line), and heart rate (red line) responses to -30 -mmHg LBNP. The vertical line indicates LBNP start. **B**, Tenseconds continuous pulmonary trunk blood flow and finger beat-to-beat blood pressure during free breathing at baseline (left) and during LBNP (right). The dark blue bar indicates expiration (Ex), and the light blue bar indicates inspiration (In). Bar plot in the middle depicts mean blood flow (left baseline and right LBNP) in liters per minute with standard deviation. **C**, Left middle cerebral artery blood flow and blood pressure at baseline (left) and during LBNP (right) with concomitant beat-to-beat blood pressure.

orthostatic stress led to profound hypotension primarily via reduction in cardiac output. Given the autonomic impairment, compensatory changes in heart rate and vascular tone through baroreflex mechanisms were insufficient.⁷ Orthostatic hypotension produced substantially reduced cerebral perfusion, which likely explains symptoms during LBNP.

Currently, MRI-compatible finger blood pressure devices, LBNP, and real-time MRI are not widely available. However, the approach may have distinct advantages. Changes in the breathing pattern or breath-holding, which are required for echocardiography, conventional ECG-synchronized cardiac MRI, or inert gas rebreathing methods, profoundly confound systemic and cerebral hemodynamic measurements, particularly in patients with autonomic failure.⁸ Previous studies either relying on indirect hemodynamic measurements⁹ or on static measurements through radionuclide ventriculography¹⁰ suggested complex hemodynamic abnormalities in patients with pure autonomic failure, resulting in orthostatic hypotension with markedly elevated blood pressure in the supine position. One potential advantage of our approach is that reliable hemodynamic measurements can be obtained in a dynamic fashion. Moreover, cerebral blood flow velocity measurements via transcranial Doppler sonography may be misleading when cerebral artery diameter changes with orthostatic stress, as shown in our patient and in previous investigations.¹¹ Had we taken only MCA blood flow velocity into account, we would have arrived at a 42.5% reduction in cerebral blood flow. Absolute MCA flow, derived from real-time MRI flow velocities and vessel diameters, revealed a total blood flow reduction of 37.6% with LBNP. The potential of real-time MRI in measuring absolute MCA flow may be particularly relevant when studying patients with orthostatic symptoms associated with cerebral vasoconstriction rather than systemic hypotension.²

LIMITATIONS

An important limitation of our study is that we did not measure end-tidal carbon dioxide, which can profoundly affect cerebral perfusion. Hyperventilation-induced cerebral vasoconstriction may contribute to orthostatic symptoms.¹² Furthermore, we did not conduct transcranial Doppler sonography for a direct comparison between methods. Future studies comparing both methodologies during physiological challenges are required. Furthermore, this is a proof-of-concept study, demonstrating the feasibility of a novel approach in assessing orthostatic cardiovascular responses in a patient with rare pure autonomic failure. Additional studies are required before more widespread use in research studies or in the clinic could be considered.

CONCLUSIONS

Our study suggests that combination of real-time MRI, LBNP, and continuous blood pressure monitoring may provide a promising new approach to study orthostatic intolerance mechanisms in human beings. In our patient with pure autonomic failure, severe orthostatic hypotension elicited through LBNP was associated with reductions in cardiac stroke volume by 44.6%, in MCA flow by 37.6%, and in pulmonary trunk flow by 40%. Real-time MRI permits dynamic functional cardiovascular examinations without breath-holding and can be combined with structural investigations of the heart and brain.

ARTICLE INFORMATION

Received April 11, 2022; accepted September 30, 2022.

Affiliations

Institute of Aerospace Medicine, German Aerospace Center (DLR), Cologne, Germany (D.A.G., J.M., A.B., A.H., J.H., K.H., J.J., J.T.); Department of Neurology, University Hospital Aachen, Aachen, Germany (A.M.); Institute for Neuroradiology, Hannover Medical School, Hannover, Germany (J.M.); Department of Internal Medicine III, Division of Cardiology, Pneumology, Angiology, and Intensive Care, University of Cologne, Germany (J.H.); Biomedical NMR, Max Planck Institute for Multidisciplinary Sciences, Göttingen, Germany (D.V., J.F.); and Medical Faculty, University of Cologne, Germany, (J.J.).

Sources of Funding

None.

Disclosures

J.J. has served as a consultant for Novartis, Boehringer-Ingelheim, and Novo-Nordisk and is cofounder of Eternygen GmbH (modest relationship). J.T. received funding from Boston-Scientific, Boehringer-Ingelheim, and Novo-Nordisk. J.-N.H. received funding from the German Aerospace Center and the German Federal Ministry of Industry and Technology (BMW, 50WB1517, 50WB1816). J.F. and D.V. are coinventors of a patent covering the real-time MRI technique used in this study. The remaining authors have no disclosures to report.

REFERENCES

1. Claassen J, Thijssen DHJ, Panerai RB, Faraci FM. Regulation of cerebral blood flow in humans: physiology and clinical implications of autoregulation. *Physiol Rev*. 2021;101:1487–1559. doi: 10.1152/physrev.00022.2020
2. Jacob G, Atkinson D, Jordan J, Shannon JR, Furlan R, Black BK, Robertson D. Effects of standing on cerebrovascular resistance in patients with idiopathic orthostatic intolerance. *Am J Med*. 1999;106:59–64. doi: 10.1016/s0002-9343(98)00364-7
3. Uecker M, Zhang S, Voit D, Karas A, Merboldt KD, Frahm J. Real-time MRI at a resolution of 20 ms. *NMR Biomed*. 2010;23:986–994. doi: 10.1002/nbm.1585
4. Untenberger M, Tan Z, Voit D, Joseph AA, Roeloffs V, Merboldt KD, Schatz S, Frahm J. Advances in real-time phase-contrast flow MRI using asymmetric radial gradient echoes. *Magn Reson Med*. 2016;75:1901–1908. doi: 10.1002/mrm.25696
5. Gerlach DA, Manuel J, Hoff A, Kronsbein H, Hoffmann F, Heusser K, Ehmke H, Diedrich A, Jordan J, Tank J, et al. Novel approach to elucidate human baroreflex regulation at the brainstem level: pharmacological testing during fMRI. *Front Neurosci*. 2019;13. doi: 10.3389/fnins.2019.00193
6. Coverdale NS, Gati JS, Opalevych O, Perrotta A, Shoemaker JK. Cerebral blood flow velocity underestimates cerebral blood flow during modest hypercapnia and hypocapnia. *J Appl Physiol* (1985). 2014;117:1090–1096. doi: 10.1152/jappphysiol.00285.2014

-
7. Furlan R, Piazza S, Bevilacqua M, Turiel M, Norbiato G, Lombardi F, Malliani A. Pure autonomic failure: complex abnormalities in the neural mechanisms regulating the cardiovascular system. *J Auton Nerv Syst*. 1995;51:223–235. doi: [10.1016/0165-1838\(94\)00135-7](https://doi.org/10.1016/0165-1838(94)00135-7)
 8. Onrot J, Bernard GR, Biaggioni I, Hollister AS, Robertson D. Direct vasodilator effect of hyperventilation-induced hypocarbia in autonomic failure patients. *Am J Med Sci*. 1991;301:305–309. doi: [10.1097/00000441-199105000-00002](https://doi.org/10.1097/00000441-199105000-00002)
 9. Chandler MP, Mathias CJ. Haemodynamic responses during head-up tilt and tilt reversal in two groups with chronic autonomic failure: pure autonomic failure and multiple system atrophy. *J Neurol*. 2002;249:542–548. doi: [10.1007/s004150200062](https://doi.org/10.1007/s004150200062)
 10. Kronenberg MW, Forman MB, Onrot J, Robertson D. Enhanced left-ventricular contractility in autonomic failure—assessment using pressure-volume relations. *J Am Coll Cardiol*. 1990;15:1334–1342. doi: [10.1016/S0735-1097\(10\)80023-3](https://doi.org/10.1016/S0735-1097(10)80023-3)
 11. Serrador JM, Picot PA, Rutt BK, Shoemaker JK, Bondar RL. MRI measures of middle cerebral artery diameter in conscious humans during simulated orthostasis. *Stroke*. 2000;31:1672–1678. doi: [10.1161/01.str.31.7.1672](https://doi.org/10.1161/01.str.31.7.1672)
 12. Carey BJ, Manktelow BN, Panerai RB, Potter JF. Cerebral autoregulatory responses to head-up tilt in normal subjects and patients with recurrent vasovagal syncope. *Circulation*. 2001;104:898–902. doi: [10.1161/hc3301.094908](https://doi.org/10.1161/hc3301.094908)