

Magnetically Controlled Devices Parallel to the Spine in Children with Spinal Muscular Atrophy

Heiko M. Lorenz, MD, Batoul Badwan, Marina M. Hecker, Konstantinos Tsaknakis, MD, Katharina Groenefeld, DDS, Lena Braunschweig, PhD, and Anna K. Hell, MD

Investigation performed at Pediatric Orthopaedics, Department of Trauma, Orthopaedic and Plastic Surgery, University Medical Center Göttingen, Göttingen, Germany

Background: Children with severe spinal deformity frequently are managed with growth-friendly implants. After initial surgery, externally controlled magnetic rods allow spinal deformity correction during growth without further surgical intervention. The ability to lengthen the spine without additional surgical procedures is especially beneficial in high-risk children, such as those with spinal muscular atrophy (SMA). The purpose of the present study was to assess the level of control of spinal deformity in a homogeneous group of patients with SMA who were managed with magnetically controlled implants for 2 years.

Methods: This prospective, nonrandomized study included 21 non-ambulatory children with type-II SMA and progressive scoliosis who were managed bilaterally with a magnetically controlled implant that was inserted parallel to the spine with use of rib-to-pelvis hook fixation. Radiographic measurements of scoliotic curves, kyphosis, lordosis, pelvic obliquity, and spinal length were performed before and after implantation of the magnetically controlled device and during external lengthening. The mean duration of follow-up was 2 years.

Results: The mean main curve of patients without prior vertical expandable prosthetic titanium rib (VEPTR) treatment decreased from 70° before implantation of the magnetically controlled device to 30° after implantation of the device. Correction was maintained during the follow-up period, with a mean curve of 31° at the time of the latest follow-up at 2.2 years. Pelvic obliquity was surgically corrected by 76% (from 17° to 4°) and remained stable during follow-up. Thoracic kyphosis could not be corrected within the follow-up period. Spinal length of children without prior spinal surgery increased by >50 mm immediately after device implantation and steadily increased at a rate of 13.5 mm/yr over the course of treatment. During treatment, 4 general complications occurred and 6 lengthening procedures failed, with 3 patients requiring surgical revision.

Conclusions: Bilateral implantation of an externally controlled magnetic rod with rib-to-pelvis fixation represents a safe and efficient method to control spinal deformity in children with SMA, achieving sufficient and stable curve correction as well as increased spinal length. The complication rate was lower than those that have been described for VEPTR and other growing rod instrumentation strategies.

Level of Evidence: Therapeutic Level IV. See Instructions for Authors for a complete description of levels of evidence.

Early surgical treatment may be necessary for children with progressive spinal deformities. In the last few decades, several growth-friendly implants, such as vertical expandable prosthetic titanium rib (VEPTR) devices^{1,2},

growing rods^{3,4}, and other rib, pelvis, and spine-based systems, have been introduced⁵. However, most of those systems require repeated surgical procedures and have been associated with a risk of implant-site infection or colonization^{6,7} and possible

Disclosure: This study was partly funded by a research grant for 10 SMA patients by NuVasive Specialized Orthopedics, Aliso Viejo, California, USA (formerly known as Ellipse Technologies, Irvine, California). The **Disclosure of Potential Conflicts of Interest** forms are provided with the online version of the article (<http://links.lww.com/JBJSOA/A26>).

Copyright © 2017 The Authors. Published by The Journal of Bone and Joint Surgery, Incorporated. All rights reserved. This is an open-access article distributed under the terms of the [Creative Commons Attribution-Non Commercial-No Derivatives License 4.0](https://creativecommons.org/licenses/by-nc-nd/4.0/) (CCBY-NC-ND), where it is permissible to download and share the work provided it is properly cited. The work cannot be changed in any way or used commercially without permission from the journal.

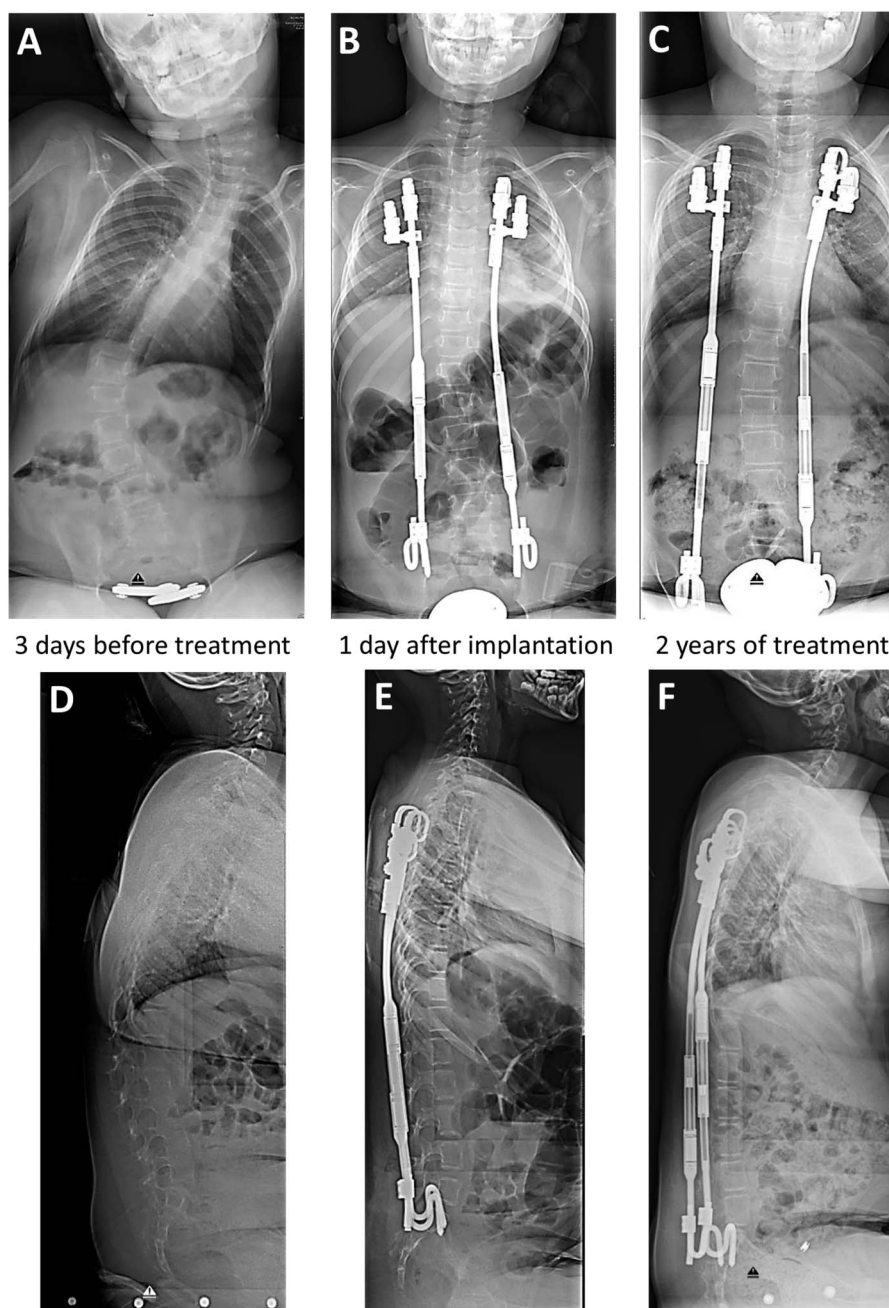


Fig. 1
 Posteroanterior (**Figs. 1-A, 1-B, and 1-C**) and lateral (**Figs. 1-D, 1-E, and 1-F**) radiographs of the spine of a 7-year-old girl with SMA and spinal deformity. The main curve was corrected from 58° (**Fig. 1-A**) before implantation of the magnetically controlled device to 12° (**Fig. 1-B**) after implantation. This result was maintained over the course of the 2-year follow-up (**Fig. 1-C**). In the sagittal plane, kyphosis in the thoracolumbar junction (**Fig. 1-D**) was initially corrected (**Fig. 1-E**), but increasing thoracic kyphosis occurred over the course of treatment (**Fig. 1-F**).

anesthesia-related complications, especially in children with spinal muscular atrophy (SMA)⁸.

To avoid repeated surgical interventions, research has focused on externally controllable devices for children. In 2009, the first magnetically controlled devices were implanted in pediatric patients with scoliosis⁹. Since then, magnetically controlled implants have been widely used to treat spinal

deformity, especially after approval by the U.S. Food and Drug Administration (FDA) in 2014^{9,10}. Most previous studies have evaluated the preliminary results associated with the use of such devices in heterogeneous groups of patients⁹⁻¹³, limiting the analysis of results because of a variety of influencing factors, such as differences in diagnosis, patient mobility, thoracic insufficiency syndrome, and weight development.

TABLE 1 Patient Characteristics*

Characteristic	Value
No. of patients	21
Female	10
Male	11
Primary implantation (<i>no. of patients</i>)	
VEPTR	4
MAGEC	17
Age at implantation† (<i>yr</i>)	
VEPTR	6.9 (5.0 to 9.2)
MAGEC	7.8 (5.0 to 11.5)
VEPTR treatment‡ (<i>n=4</i>)	
No. of lengthening procedures	3.5 (2 to 5)
Duration of treatment (<i>mo</i>)	30.3 (26.4 to 38.4)
MAGEC treatment‡ (<i>n=21</i>)	
No. of lengthening procedures	8.2 (5 to 9)
Duration of treatment (<i>mo</i>)	26.7 (17.3 to 33.3)
Complications (<i>no. of patients</i>)	4 (19%)
Implant disconnected, surgical revision	1
Rib fracture with surgery	1
Rib fracture without surgery	1
Superficial wound infection, IV antibiotics	1
Implant expansion failures	
No. of failures implant expansion failures (<i>no. of patients</i>)	6 (3)
BMI of patients with implant expansion failure (<i>percentile</i>)	>97%, >90%, 50%
Surgical revision because of expansion failure‡ (<i>no. of patients</i>)	1

*VEPTR = vertical expandable prosthetic titanium rib, MAGEC = magnetically controlled device, IV = intravenous, and BMI = body mass index. †The values are given as the mean, with the range in parentheses. ‡Implant testing without exchange.

To our knowledge, we are the first to describe the results of a prospective investigation involving a homogeneous group of children with spinal deformity due to SMA who were managed with bilateral insertion of a magnetically controlled rod with rib-to-pelvis fixation^{2,14}. This implant strategy leaves the spine untouched both for intrathecal medical administration and for later definitive spinal fusion at the beginning of puberty. All patients had the same diagnosis, the same implant construct, the same lengthening protocol, and the same time intervals between expansion procedures. By eliminating influencing factors, this unique study design allowed us to examine solely the effect of magnetically controlled devices.

Materials and Methods

Following ethics committee approval, we performed a prospective cohort study involving 21 non-ambulatory children with type-II SMA who underwent bilateral insertion of a magnetically controlled implant (MAGEC [MAGnetic Expansion Control]; Ellipse Technologies) with use of VEPTR rib-to-pelvis fixation² at the University Medical

Center in Göttingen, Germany, between 2011 and 2015. All patients were followed for at least 2 years after implantation of the magnetically controlled device and, if applicable, during VEPTR treatment with repeated lengthening procedures. The first outpatient expansion procedure was performed 5 months after the insertion of the magnetically controlled device, with subsequent lengthening procedures of 5 mm being conducted approximately every 3 months. Clinical data relative to sex, body mass index (BMI), age at initial surgery, duration of treatment, and complications were obtained.

Measurements were made on 744 digital radiographs with use of a radiographic processing program (Centricity; GE Healthcare). All radiographs that met specific criteria (including sitting anteroposterior and lateral radiographs made before and after surgical implantation of magnetically controlled device, sitting anteroposterior and lateral radiographs made after [and, if applicable, before] every expansion procedure, and radiographs made during VEPTR treatment prior to the implantation of the magnetically controlled device) were analyzed.

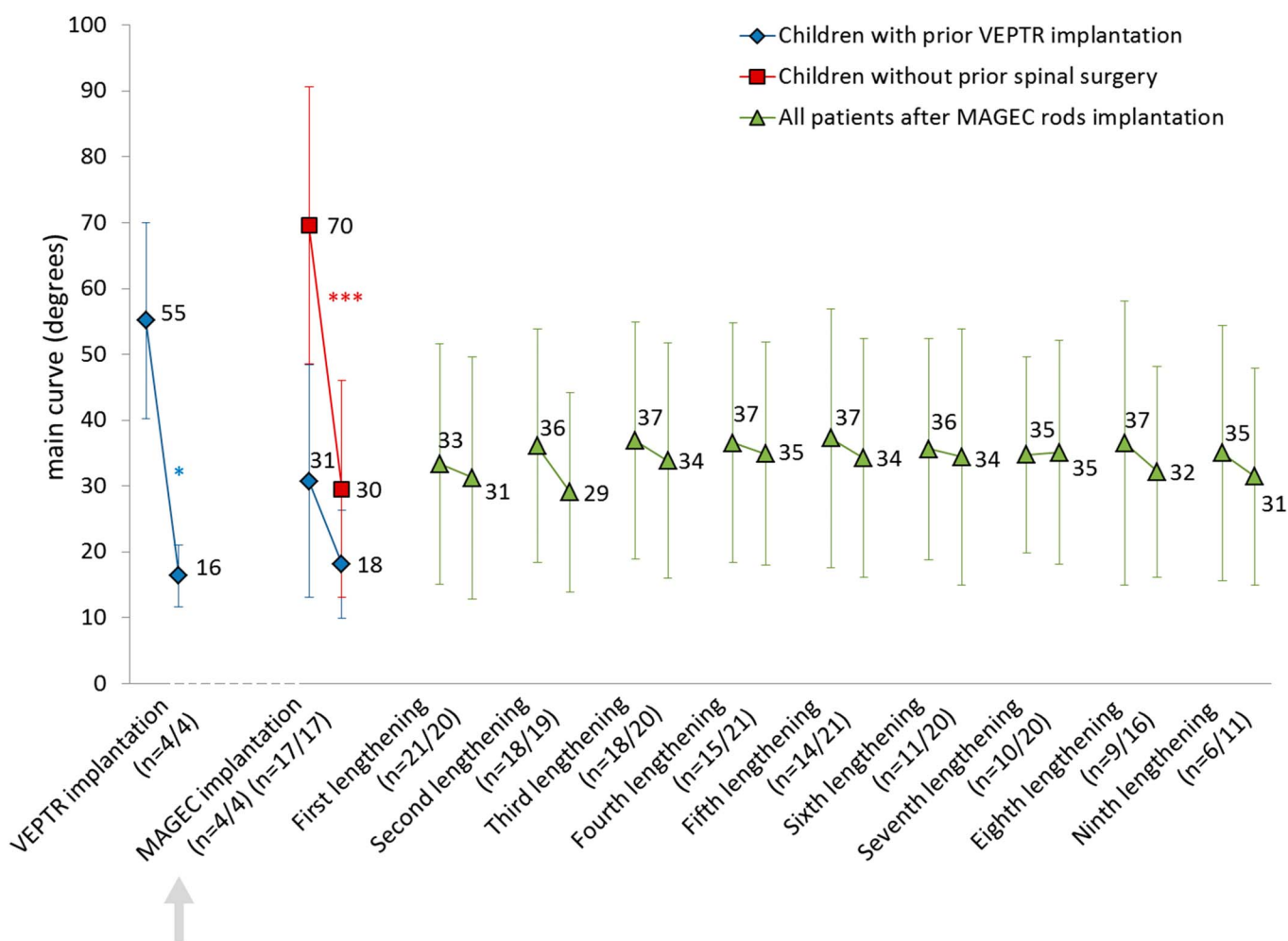


Fig. 2
Chart showing the development of the main curve angle before and after each intervention. The values are given as the mean, and the I-bars indicate the standard deviation. The first n value shown in parentheses indicates the number of radiographs analyzed before each intervention, and the second n value indicates the number of radiographs analyzed after each intervention. *P < 0.05. ***P < 0.001.

The anteroposterior radiographs were used to measure the Cobb angle¹⁵ of the main thoracic, thoracolumbar, or lumbar curve as well as the pelvic obliquity (defined as the angle between a horizontal line and a straight line between the iliac crests).

The lateral radiographs were used to measure kyphosis, lordosis, and spinal length. Spinal length was measured as the distance between the vertebral body of the most cranial instrumented rib (usually T3 or T4) and the sacrum. This measurement of spinal length was chosen because of the lack of head control, and therefore the very flexible and variable junctional kyphosis, in children with SMA.

For the evaluation of interobserver error, all measurements were made by 2 independent investigators. The data were analyzed statistically with use of Excel software (Microsoft). Significance was assessed with use of the Student t test at 3 different levels: $p < 0.05$, $p < 0.01$, and $p < 0.001$.

Results

Patient Demographics

Data on 21 scoliotic children (10 female, 11 male) with SMA were reviewed before and after the surgical implantation of the magnetically controlled device and during subsequent lengthening procedures (mean, 8.2 lengthening procedures over 2.2 years). Four of the 21 patients had previously undergone bilateral implantation of a VEPTR device with rib-to-pelvis fixation at a mean of 2.5 years prior to the implantation of the magnetically controlled device; during the period after the implantation of the VEPTR device and before the implantation of the magnetically controlled device, these 4 patients had undergone a mean of 3.5 lengthening procedures. During conversion surgery, the initial fixation anchors were retained in all 4 patients. All 21 patients were managed with bilateral insertion of the magnetically controlled device with use of VEPTR rib-to-pelvis fixation (Fig. 1, Table I).

Four patients experienced complications during the treatment period. One patient had implant dislocation because

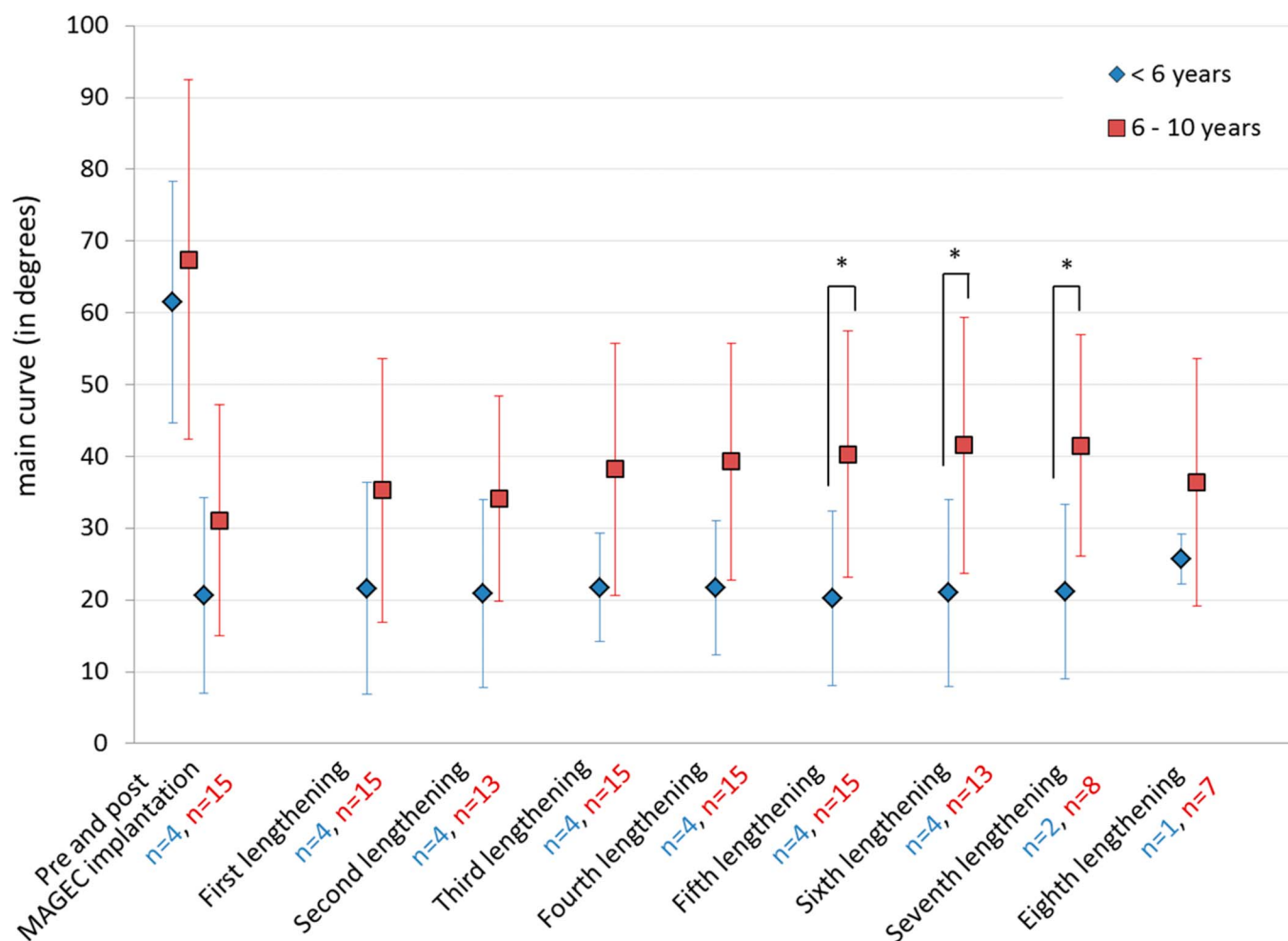


Fig. 3
Chart showing the age-dependent development of the main curve angle after each intervention. The values are given as the mean, and the I-bars indicate the standard deviation. Patients are grouped according to their age (<6 years of age and 6 to 10 years of age). The n values indicate the numbers of patients in each age group. Two children (>10 years of age) were excluded from the analysis. *P < 0.05.

of a difference in implant diameters and underwent surgical correction with use of a connector. Two patients experienced a rib fracture; 1 required surgical revision of the rib cradle. One patient had a superficial wound infection that was treated with intravenous antibiotics without implant exchange.

The patients underwent a total of 172 attempted lengthening procedures. There were a total of 6 failures (3.5%) in 3 patients, 2 of whom had a BMI above the 90th percentile. One obese patient experienced 4 failures, leading to a surgical revision without implant exchange after intraoperative testing. In the 2 patients who experienced the other 2 failures, subsequent lengthening sessions were successful, thus excluding implant failure as the reason for the initial unsuccessful lengthening.

Radiographic Results

Main Curve

In the 17 patients who had not undergone prior spinal surgery, the mean Cobb angle of the main thoracic or thoracolumbar

curve was corrected from 70° to 30° ($p < 0.001$) after implantation of the magnetically controlled device. In the remaining 4 patients, the mean Cobb angle had initially decreased from 55° to 16° ($p = 0.017$) after the implantation of the previous VEPT device but had worsened to 31° after a mean duration of follow-up of 2.5 years. However, after the implantation of the magnetically controlled device, the mean Cobb angle in these patients decreased from 31° to 18° ($p = 0.098$). In all patients, the overall curve correction was effectively maintained during the 2-year period following the implantation of the magnetically controlled device with a final value of 31° (Fig. 2).

In children younger than 6 years of age ($n = 4$), there was greater initial correction and better control of scoliosis at the time of the latest follow-up (Fig. 3).

Pelvic Obliquity

Pelvic obliquity was significantly reduced from 17° to 4° following bilateral implantation of either the magnetically

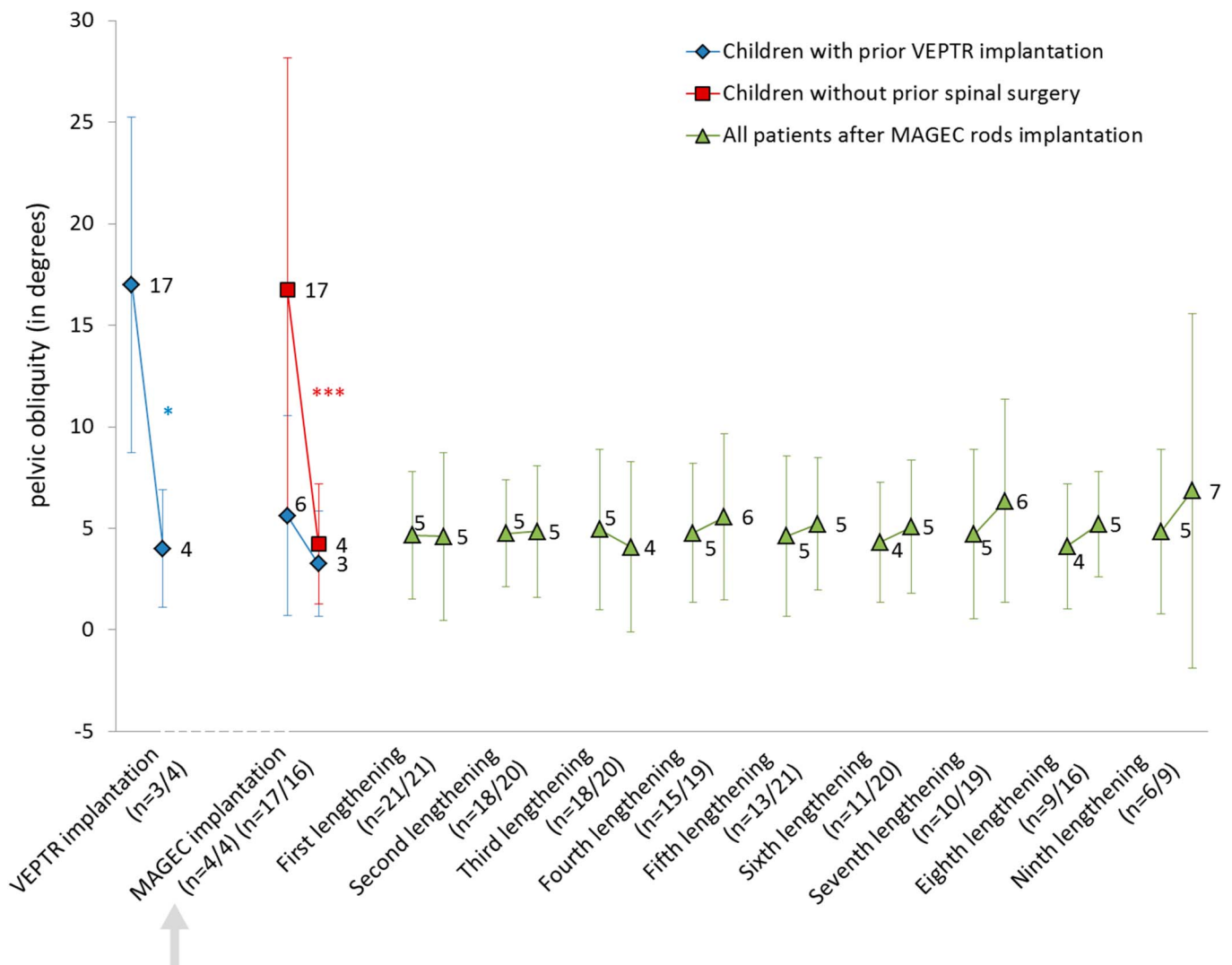


Fig. 4

Chart showing the development of the pelvic obliquity before and after each intervention. The values are given as the mean, and the I-bars indicate the standard deviation. The first n value shown in parentheses indicates the number of radiographs analyzed before each intervention, and the second n value indicates the number of radiographs analyzed after each intervention. *P < 0.05. ***P < 0.001.

controlled device (n = 17) or the VEPTR device (n = 4) (p < 0.001 and p = 0.028, respectively) (Fig. 4). Pelvic obliquity remained at a low level throughout the entire follow-up period, which lasted for as long as 2.8 years and involved as many as 9 lengthening procedures.

Kyphosis

Before implantation of the magnetically controlled device, the mean thoracic kyphosis measured 44° in patients who had had prior VEPTR treatment and 46° in those who had not (Fig. 5). Thoracic kyphosis showed a trend for correction immediately after implantation of the magnetically controlled device but deteriorated over time, reaching baseline values during the follow-up period despite routine lengthening procedures.

Lordosis

Before implantation of the magnetically controlled device, the mean lordosis values were 35° in patients who had had prior VEPTR treatment and 30° in those who had not (Fig. 6). Treatment with the magnetically controlled device resulted in decreased lordosis, causing relative kyphosis during longer therapy with the device. However, these changes were not significant.

Spinal Length

Before implantation of the magnetically controlled device, the mean spinal length was 287 mm in patients who had had prior VEPTR treatment (mean age, 9.5 years) and 234 mm in those who had not (mean age, 7.5 years). The latter group had an increase in spinal length to 285 mm (p < 0.001) immediately

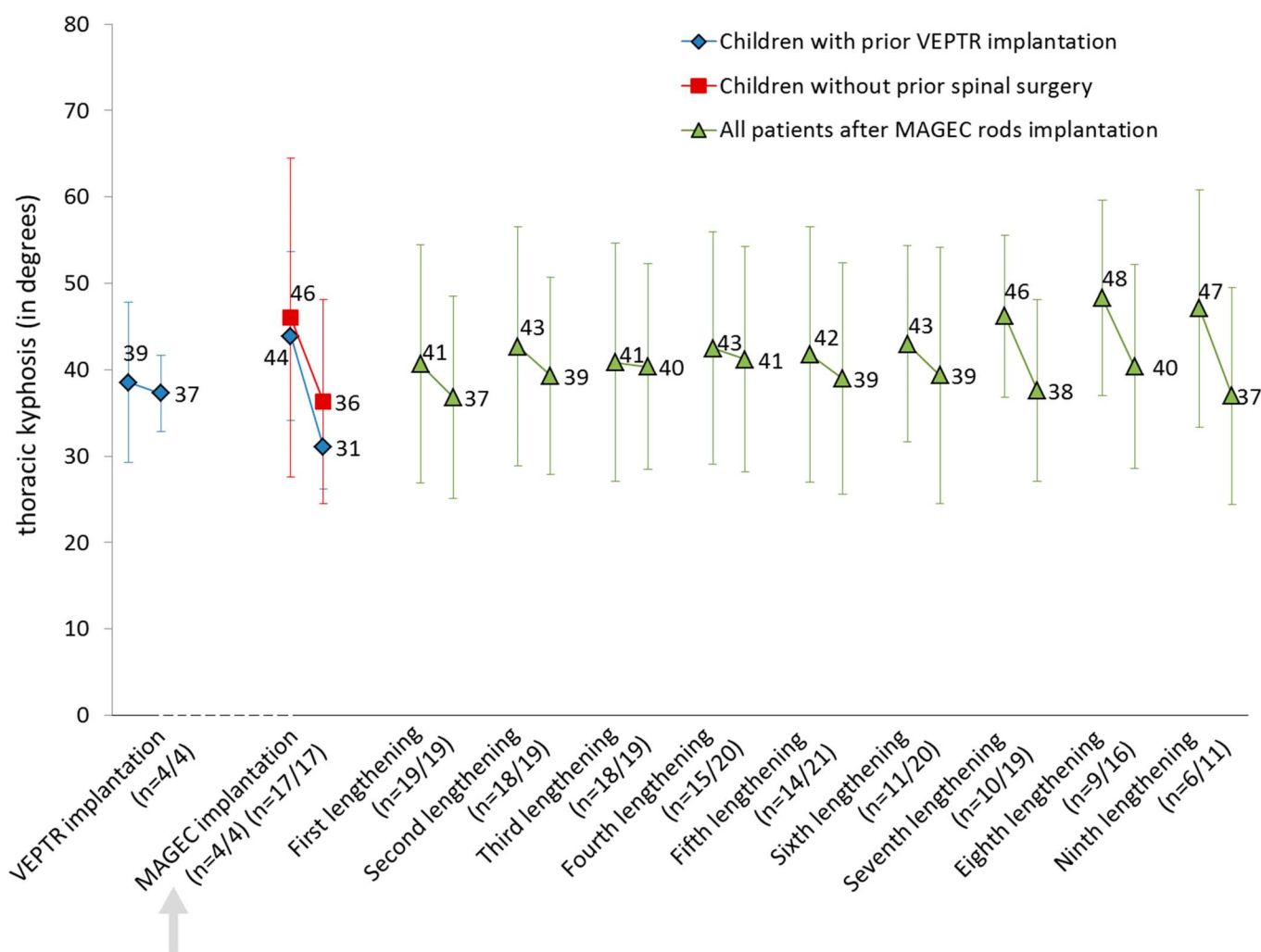


Fig. 5
Chart showing the development of age-adapted thoracic kyphosis before and after each intervention. The values are given as the mean, and the I-bars indicate the standard deviation. The first n value shown in parentheses indicates the number of radiographs analyzed before each intervention, and the second n value indicates the number of radiographs analyzed after each intervention.

after implantation of the magnetically controlled device. Spinal length increased steadily over the course of treatment, with an average gain of 13.5 mm/yr (Fig. 7).

Discussion

Severe spinal deformity usually develops at a young age in children with SMA. In the majority of cases, conservative brace treatment cannot be used because of severe breathing impairment, thus increasing the likelihood of early surgical treatment. In the last few decades, several growth-friendly implants have been used, most of which require repeated surgical lengthening.

In an effort to reduce the number of surgical procedures and thereby minimize the surgical, narcotic, and infectious risks associated with such procedures, externally controlled magnetic implant systems, including the MAGEC device, have been developed in recent years. A number of studies in the literature have evaluated the preliminary results associated with

magnetically controllable growing rods⁹⁻¹³; however, most of those studies have focused on heterogeneous pediatric populations with short-term follow-up.

The present prospective study focused on a homogenous population of children with SMA and scoliotic deformity who were followed for >2 years. All patients underwent the same surgical procedure involving the bilateral implantation of a magnetically controlled device with rib-to-pelvis fixation, and all were managed with the same follow-up protocol involving 5 mm of lengthening at each follow-up visit, with the first lengthening procedure being performed 5 months after surgery and serial procedures being performed every 3 months. Four patients had had prior VEPTTR treatment with the same fixation construct before the insertion of magnetically controlled rods.

In our group of patients, scoliosis was adequately controlled with use of noninvasive magnetic growing rods. Before implantation of these rods, the mean main curve angle was 55° in patients who had had prior VEPTTR treatment and 70° in

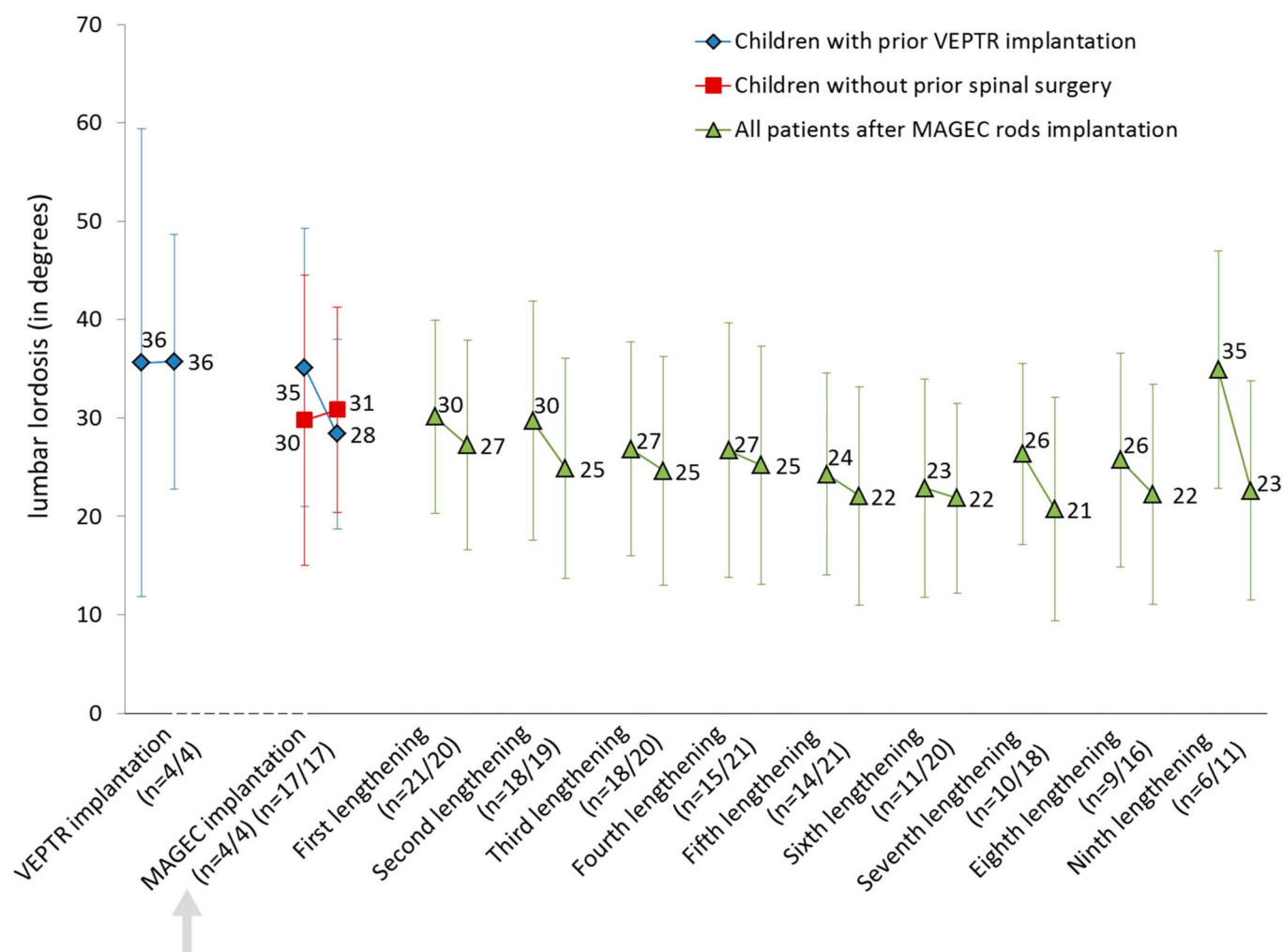


Fig. 6
Chart showing the development of age-adapted lumbar lordosis before and after each intervention. The values are given as the mean, and the I-bars indicate the standard deviation. The first n value shown in parentheses indicates the number of radiographs analyzed before each intervention, and the second n value indicates the number of radiographs analyzed after each intervention.

those who had not; both values were consistent with those reported in previous studies (range, 55° to 89°)^{9-13,16-19}. Following the initial surgical procedure, the main spinal curve was corrected by 71% in patients who received the VEPTR device and by 57% in those who received the MAGEC device, with both values exceeding the deformity correction reported in previous studies analyzing either magnetically controlled implants in patients with scoliosis (range, 32° to 63°)^{9-13,16-19} or growing rods in patients with SMA (range, 49° to 62°)⁹⁻¹³. In both groups, correction of the main curve was maintained successfully during the course of treatment. At the time of the latest evaluation (after a mean duration of follow-up of 2.2 years), the curve was still significantly reduced to the same extent as it was immediately following implantation of the magnetically controlled device. These values reflect the flexibility of spinal deformity in patients with SMA, which has been described previously²⁰. However, to our knowledge, the present study is the first in which a bilateral externally magnetically

controlled implant construct with rib-to-pelvis fixation has been shown to maintain favorable results in children with flexible scoliosis for a mean of 2 years.

The severity of the main curve varied considerably among individual patients in the present study (range, 26° to 98°) because, when magnetically controlled implants were introduced, they initially were used for older children with more-severe curves; however, as the success of this method was acknowledged by pediatricians and patient organizations over subsequent years, the method started to be used for younger children with less-severe deformities.

In the present study, younger patients tended to have better scoliosis correction than older patients during the 2-year follow-up period (mean improvement, 65% compared with 40%). This finding might reflect the beginning of relative rigidity or increased weight in older patients. However, the presented data are based on a relatively small subset of only 4 patients who were <6 years of age.

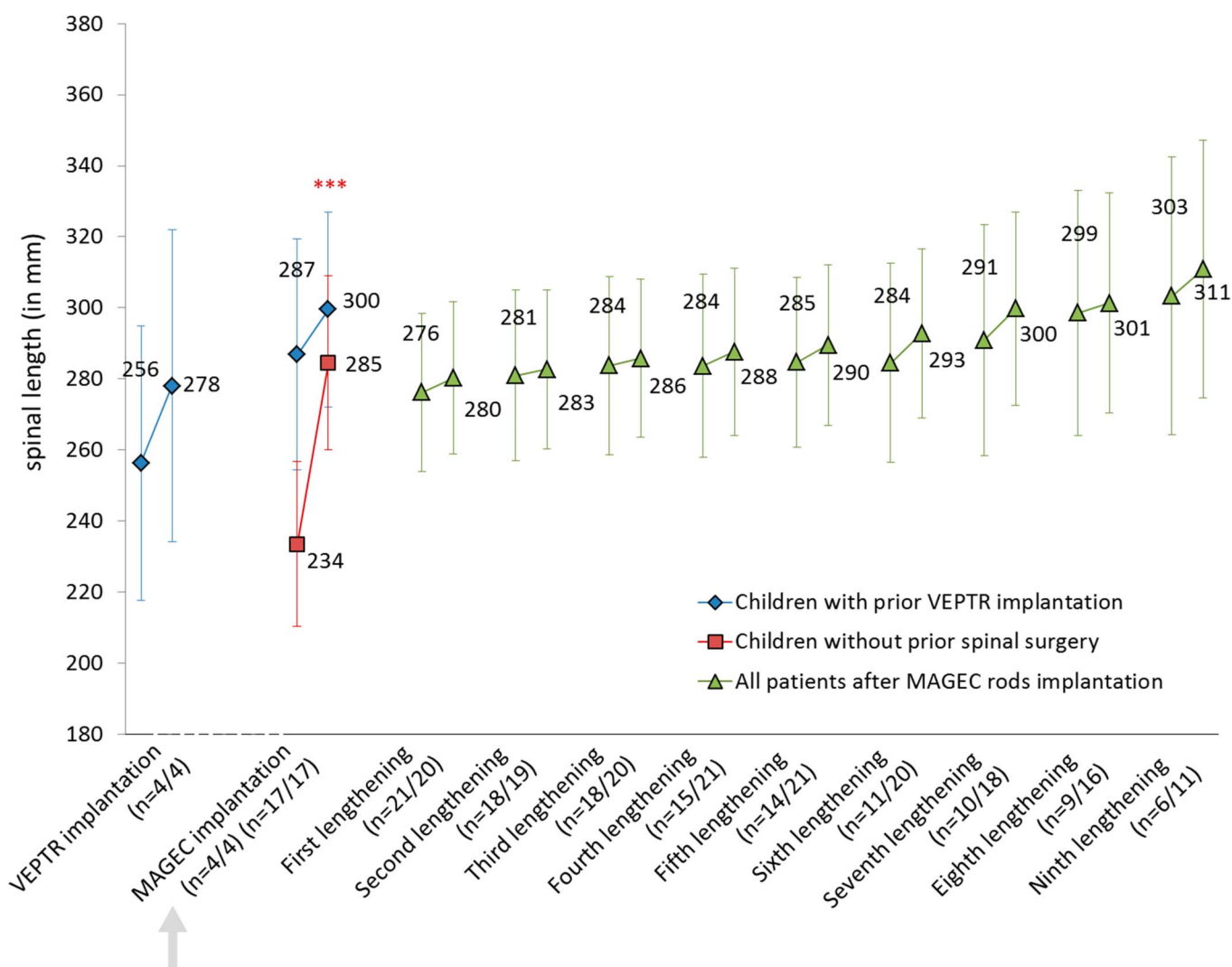


Fig. 7
Chart showing the development of spinal length before and after each intervention. The values are given as the mean, and the I-bars indicate the standard deviation. The first n value shown in parentheses indicates the number of radiographs analyzed before each intervention, and the second n value indicates the number of radiographs analyzed after each intervention. ***P < 0.001.

Pelvic obliquity also was found to be responsive to the described treatment method. The severity of pelvic obliquity was reduced considerably and only increased slightly during the follow-up period, indicating that the bilateral insertion of a magnetically controlled device with use of rib-to-pelvic fixation is reliable for correcting pelvic obliquity in children with SMA.

Kyphosis was not found to be effectively controlled by the implantation of magnetic growing rods. Kyphosis increased over time and exceeded baseline values, a finding that was consistent with those of recent studies^{10,11,21-23}. Possible reasons for the inefficient control of kyphosis could be any proximal junctional kyphosis, flexible implant anchors (e.g., ribs and pelvis), and lack of trunk and head control^{22,24}. However, as all patients in the present study were diagnosed with SMA and had limited head control,

standardized radiographic imaging with the patients in a sitting position was impossible and therefore this hypothesis could not be validated.

During surgery, our patients had an increase of >50 mm in spinal length, emphasizing the immediate impact of this procedure in patients with SMA and spinal deformity. During follow-up, spinal length continued to increase steadily at a rate of 13.5 mm/yr, which is slightly greater than the rate suggested for healthy children of that age (11 mm/yr)²⁵. With a lengthening of 5 mm 4 times per year, an annual increase of 20 mm would be expected. The discrepancy between our expected annual increase and the observed one can be explained by variations in lengthening intervals due to sickness or other reasons and by implant migration, which has been previously observed in patients with VEPTTR constructs^{26,27}. Discrepancy between the intended and the measured values has been

previously reported in patients with magnetically controlled implants¹³.

Sankar et al. suggested a “law of diminishing returns,”²⁸ positing a decreased gain in spinal length with each subsequent expansion procedure. However, as a result of the use of smaller intervals between lengthening procedures, this phenomenon was avoided in our patients, at least during the first 2 years^{9,28}, although further investigations with longer follow-up are needed.

Following the 193 interventions in the present study, there were 4 general complications, 2 of which required surgical treatment, and 6 failed implant expansions, 1 of which led to surgery. Much higher complication rates of growing rods (up to 57%) have been described in the literature^{13,29}. Over a 2-year follow-up period, the magnetically controlled implants in the present study had superior results in terms of infection, skin abrasion, and surgical revisions when compared with other methods (e.g., VEPTR, growing rods)^{22,23,29}. However, in children with a very high BMI, magnetically controlled implants may fail to extend, probably because of increased soft-tissue distances between the external controller and the implants as well as increased pressure.

Our data show the enduring corrective effect of externally controlled magnetic implants on scoliosis and pelvic obliquity in children with SMA and spinal deformity. Contrary to most other studies^{10-12,17-19}, our study was a prospective investigation focusing on a patient population that was homogenous in terms of diagnosis, surgical technique, follow-up protocol, and duration of treatment. However,

further studies analyzing long-term results for different scoliotic entities might be helpful to fully understand the potential of externally controlled implants for pediatric spine correction.

In conclusion, bilateral implantation of an externally controlled magnetic device with rib-to-pelvis fixation can significantly reduce scoliotic deformity and can normalize pelvic obliquity in children with variable spinal deformity and SMA. The favorable results of our study were maintained during repeated lengthening procedures every 3 months over the course of an average 2-year follow-up period. The complication rate was lower than previously described in surgically treated pediatric spine populations. ■

Heiko M. Lorenz, MD¹
Batoul Badwan¹
Marina M. Hecker¹
Konstantinos Tsaknakis, MD¹
Katharina Groenefeld, DDS¹
Lena Braunschweig, PhD¹
Anna K. Hell, MD¹

¹Pediatric Orthopaedics, Department of Trauma, Orthopaedic and Plastic Surgery, University Medical Center Göttingen, Göttingen, Germany

E-mail address for A.K. Hell: anna.hell@med.uni-goettingen.de

ORCID iD for A.K. Hell: [0000-0002-6655-7130](https://orcid.org/0000-0002-6655-7130)

References

- Hell AK, Hefti F, Campbell RM Jr. [Treatment of congenital scoliosis with the vertical expandable prosthetic titanium rib implant]. *Orthopade*. 2004 Aug;33(8):911-8. German.
- Campbell RM Jr, Smith MD, Hell-Vocke AK. Expansion thoracoplasty: the surgical technique of opening-wedge thoracostomy. *Surgical technique*. *J Bone Joint Surg Am*. 2004 Mar;86(Suppl 1):51-64.
- Klemme WR, Denis F, Winter RB, Lonstein JW, Koop SE. Spinal instrumentation without fusion for progressive scoliosis in young children. *J Pediatr Orthop*. 1997 Nov-Dec;17(6):734-42.
- Akbarnia BA, Marks DS, Boachie-Adjei O, Thompson AG, Asher MA. Dual growing rod technique for the treatment of progressive early-onset scoliosis: a multicenter study. *Spine (Phila Pa 1976)*. 2005 Sep 01;30(17)(Suppl):S46-57.
- Skaggs DL, Akbarnia BA, Flynn JM, Myung KS, Sponseller PD, Vitale MG; Wall Chest and Spine Deformity Study Group; Growing Spine Study Group; Pediatric Orthopaedic Society of North America; Scoliosis Research Society Growing Spine Study Committee. A classification of growth friendly spine implants. *J Pediatr Orthop*. 2014 Apr-May;34(3):260-74.
- Plaass C, Hasler CC, Heining U, Studer D. Bacterial colonization of VEPTR implants under repeated expansions in children with severe early onset spinal deformities. *Eur Spine J*. 2016 Feb;25(2):549-56. Epub 2015 May 15.
- Wagner L, Braunschweig L, Eiffert H, et al. Detection of bacteria colonizing titanium spinal implants in children. Unpublished data.
- Islander G. Anesthesia and spinal muscle atrophy. *Paediatr Anaesth*. 2013 Sep;23(9):804-16. Epub 2013 Apr 19.
- Cheung KMC, Cheung JPY, Samartzis D, Mak KC, Wong YW, Cheung WY, Akbarnia BA, Luk KD. Magnetically controlled growing rods for severe spinal curvature in young children: a prospective case series. *Lancet*. 2012 May 26;379(9830):1967-74. Epub 2012 Apr 19.
- Akbarnia BA, Cheung K, Noordeen H, Elsebaie H, Yazici M, Dannawi Z, Kabirian N. Next generation of growth-sparing techniques: preliminary clinical results of a magnetically controlled growing rod in 14 patients with early-onset scoliosis. *Spine (Phila Pa 1976)*. 2013 Apr 15;38(8):665-70.
- Dannawi Z, Altaf F, Harshavardhana NS, El Sebaie H, Noordeen H. Early results of a remotely-operated magnetic growth rod in early-onset scoliosis. *Bone Joint J*. 2013 Jan;95-B(1):75-80.
- Hickey BA, Towriss C, Baxter G, Yasso S, James S, Jones A, Howes J, Davies P, Ahuja S. Early experience of MAGEC magnetic growing rods in the treatment of early onset scoliosis. *Eur Spine J*. 2014 Apr;23(Suppl 1):S61-5. Epub 2014 Jan 11.
- Lebon J, Batailler C, Wargny M, Choufani E, Violas P, Fron D, Kieffer J, Accabdled F, Cunin V, De Gauzy JS. Magnetically controlled growing rod in early onset scoliosis: a 30-case multicenter study. *Eur Spine J*. 2017 Jun;26(6):1567-76. Epub 2016 Dec 31.
- Hell AK, Groenefeld K, Tsaknakis K, Braunschweig L, Lorenz HM. Combining bilateral magnetically controlled implants inserted parallel to the spine with rib to pelvis fixation - surgical technique and early results. Unpublished data.
- Cobb JR. Outline for the study of scoliosis. *AAOS*. 1948(5):261-75.
- Emans JB, Caubet JF, Ordonez CL, Lee EY, Ciarlo M. The treatment of spine and chest wall deformities with fused ribs by expansion thoracostomy and insertion of vertical expandable prosthetic titanium rib: growth of thoracic spine and improvement of lung volumes. *Spine (Phila Pa 1976)*. 2005 Sep 01;30(17)(Suppl):S58-68.
- Lenhart RL, Youlo S, Schroth MK, Noonan KJ, McCarthy J, Mann D, Hetzel S, Sund SA, Halanski MA. Radiographic and respiratory effects of growing rods in children with spinal muscular atrophy. *J Pediatr Orthop*. 2016 Sep 15. [Epub ahead of print].
- Zebala LP, Bridwell KH, Baldus C, Richards SB, Dormans JP, Lenke LG, Auerbach JD, Lovejoy J. Minimum 5-year radiographic results of long scoliosis fusion in juvenile spinal muscular atrophy patients: major curve progression after instrumented fusion. *J Pediatr Orthop*. 2011 Jul-Aug;31(5):480-8.
- McElroy MJ, Shaner AC, Crawford TO, Thompson GH, Kadakia RV, Akbarnia BA, Skaggs DL, Emans JB, Sponseller PD. Growing rods for scoliosis in spinal muscular atrophy: structural effects, complications, and hospital stays. *Spine (Phila Pa 1976)*. 2011 Jul 15;36(16):1305-11.
- Gantner AS, Braunschweig L, Tsaknakis K, Lorenz HM, Hell AK. Curve progression in children with spinal deformity after removal of VEPTR (vertical expandable prosthetic titanium rib) devices. Unpublished data.

- 21.** Gantner AS, Braunschweig L, Tsaknakis K, Lorenz HM, Hell AK. Spinal deformity changes in children with long-term vertical expandable prosthetic titanium rib (VEPTR) treatment. *Spine J*. 2017 Aug 22;S1529-9430(17)30921-X. Epub 2017 Aug 22.
- 22.** Hasler CC, Mehrkens A, Hefti F. Efficacy and safety of VEPTR instrumentation for progressive spine deformities in young children without rib fusions. *Eur Spine J*. 2010 Mar;19(3):400-8. Epub 2009 Dec 31.
- 23.** Samdani AF, Ranade A, Dolch HJ, Williams R, St Hilaire T, Cahill P, Betz RR. Bilateral use of the vertical expandable prosthetic titanium rib attached to the pelvis: a novel treatment for scoliosis in the growing spine. *J Neurosurg Spine*. 2009 Apr;10(4):287-92.
- 24.** Thompson GH, Akbarnia BA, Campbell RM Jr. Growing rod techniques in early-onset scoliosis. *J Pediatr Orthop*. 2007 Apr-May;27(3):354-61.
- 25.** Canavese F, Dimeglio A. Normal and abnormal spine and thoracic cage development. *World J Orthop*. 2013 Oct 18;4(4):167-74.
- 26.** Campbell RM Jr, Smith MD. Thoracic insufficiency syndrome and exotic scoliosis. *J Bone Joint Surg Am*. 2007 Feb;89(Suppl 1):108-22.
- 27.** Groenefeld B, Hell AK. Ossifications after vertical expandable prosthetic titanium rib treatment in children with thoracic insufficiency syndrome and scoliosis. *Spine (Phila Pa 1976)*. 2013 Jun 01;38(13):E819-23.
- 28.** Sankar WN, Skaggs DL, Yazici M, Johnston CE 2nd, Shah SA, Javidan P, Kadakia RV, Day TF, Akbarnia BA. Lengthening of dual growing rods and the law of diminishing returns. *Spine (Phila Pa 1976)*. 2011 May 01;36(10):806-9.
- 29.** Bess S, Akbarnia BA, Thompson GH, Sponseller PD, Shah SA, El Sebaie H, Boachie-Adjei O, Karlin LI, Canale S, Poe-Kochert C, Skaggs DL. Complications of growing-rod treatment for early-onset scoliosis: analysis of one hundred and forty patients. *J Bone Joint Surg Am*. 2010 Nov 03;92(15):2533-43. Epub 2010 Oct 1.