

## Original article

**Cone-beam-computed-tomography of the symmetry of root canal anatomy in mandibular incisors**Steffi Baxter<sup>1)</sup>, Marie Jablonski<sup>1,2)</sup>, and Michael Hülsmann<sup>1)</sup><sup>1)</sup>Department of Preventive Dentistry, Periodontology and Cariology, University of Göttingen, Göttingen, Germany<sup>2)</sup>Private Dental Practice, Hanau, Germany

(Received March 20, 2019; Accepted June 13, 2019)

**Abstract:** This study aimed to evaluate the prevalence of internal symmetry (the number and morphology of root canals) in the mandibular incisors using cone beam computed tomography (CBCT). A total of 302 CBCT scans involving 1,208 mandibular incisors were evaluated using the Vertucci's classification regarding the number and configuration of root canals. The central mandibular incisors exhibited two root canals in 22.6% of patients and lateral incisors in 24.3% of patients. Most teeth (76.4%) had a type I configuration (a single root canal, 1-1), 21.7% had type II (2-1), 1.1% had type V (1-2), and 0.8% had type IV (2-2). Teeth with a type-III configuration (1-2-1) were not found. In total, 17.5% of patients had a symmetric appearance of the two-canal central mandibular incisors and 20.5% had a bilateral appearance of the two-canal lateral incisors. Moreover, in 12.3% of the patients, all four incisors showed two root canals. The highest degree of symmetry was found in incisors that had one root canal (central incisors: 217 of 302, lateral incisors: 229 of 302), followed by type 2-1 incisors (central incisors 50, lateral incisors 58). The influence of sex and age on the prevalence of symmetries was not significant. Concluding, the internal anatomy of the mandibular incisors cannot not be sufficiently predicted from the root canal anatomy of the contralateral tooth. Thorough clinical and radiographic inspection of each tooth remains mandatory to address the internal anatomy of the mandibular incisors correctly.

Keywords: CBCT, mandibular incisor, root canal anatomy, symmetry

**Introduction**

A good knowledge of the internal and external anatomies of teeth is essential for successful root canal treatment. Neglecting these parameters may result in severe complications such as ledging and perforations, missing root canals, the unnecessary removal of dental hard tissue, as well as incomplete preparation, disinfection, and obturation.

The mandibular incisors have repeatedly been shown to have major anatomical problems such as isthmi, oval cross-sections, and double root canals [1]. Not all of these can be precisely and sufficiently viewed using two-dimensional radiographs. Clinically and radiographically, a number of configurations have been identified as being typical for incisors with double root canals; e.g., the eccentric localization of a root canal orifice, double outer contours of the root, or sudden narrowing of the root canal [2]. In studies using different evaluation techniques, such as clearing, micro-computed tomography (CT), or cone beam CT (CBCT), the prevalence of mandibular incisors with two root canals has been reported to range from 3% [3], 11.5% [4] to 41.1% [5]. Sert et al. detected a second root canal in 68% of central and 63% of lateral mandibular incisors in a Turkish population [6]. These discrepancies primarily result from ethnic differences in the root and root canal anatomies as well as from widely differing investigation techniques ranging from radiography, clearing, and histology to contemporary techniques using CBCT or micro-CT.

As demonstrated in several studies, missed root canals significantly

contribute to endodontic treatment failure, with a prevalence of approximately 8% [7]. A previously untreated root canal was detected in 42% of retreatments [8]. A second mesio-buccal root canal was present in 8% of retreatments for the maxillary molars [9,10]. Clinically, the presence of a second root canal in the mandibular incisors may require a modified access cavity preparation [11,12] or modifications in beam angulation for radiography [13]. Additionally, root canal preparation has to be adjusted according to the morphology of the root canal systems.

In a CBCT study, Monsarrat et al. investigated the anatomical inter-relationships among permanent teeth. They determined whether a certain anatomy in one tooth is associated with that in another tooth. The number of root canals was recorded using 106 CBCT scans with a total of 2,424 teeth studied. They found that patients with a second root canal in the mandibular incisors also had an increased risk of having a mandibular premolar with an additional root canal, with an odds ratio of 3.7 [14]. A number of studies have been published on the symmetry of the internal and external anatomy of human teeth [15-22]. A high degree of symmetry regarding the number and configuration of root canals could be helpful for endodontic treatment planning regarding the size and location of the access cavity, which should be related to the estimated number of root canals and preparation planning for accurately addressing the configuration of root canals.

For successful root canal treatment, all root canals of a tooth need to be detected and treated. Especially in the mandibular incisors, it is difficult at times to locate the lingual root canal, if present. Therefore, it would be of interest to know more about the prevalence of bilateral symmetry regarding the anatomy of the mandibular incisors regarding the number of root canals and internal anatomy.

Accordingly, the present study aimed to evaluate the prevalence of internal symmetry in the mandibular incisors regarding the number and configuration of root canals using CBCT scans obtained for other purposes.

**Materials and Methods**

The study was approved by the Ethics Committee of the University (no. 7/6/11).

A total of 1,700 CBCT scans from a private dental office, obtained for reasons not related to this study, were retrospectively evaluated. The dental office's main focus was general dentistry, dental surgery, and dental implantology, which were the primary reasons for obtaining large field-of-view CBCT scans.

The study inclusion criteria were as follows:

- patients aged  $\geq 18$  years
- all the mandibular incisors showed complete root development
- there were no radiographic signs of apical resorption
- there were no radiographic signs of previous root canal treatment or apical surgery in the mandibular incisors
- there were clearly visible root canal contours without severe calcification signs
- sufficient quality of CBCT scans
- consent of patients to scientific evaluation of their anonymized scans

The exclusion criteria were as follows:

- missing mandibular incisors
- incomplete root development
- previous root canal treatment or apical surgery
- radiographical signs of apical resorption
- no visible root canal contours with severe calcification signs

Correspondence to Dr. Steffi Baxter, Department of Preventive Dentistry, Periodontology and Cariology, University of Göttingen, Robert-Koch-Str. 40, Göttingen 37075, Germany  
Fax: +49-551-3922037 Email: steffi.baxter@med.uni-goettingen.de

Color figures can be viewed in the online issue at J-STAGE.

doi.org/10.2334/josnusd.19-0113

DN/JST.JSTAGE/josnusd/19-0113

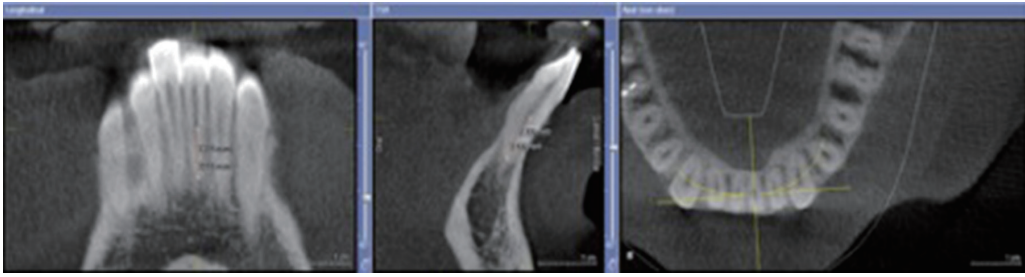


Fig. 1 Vertucci's classification type 1-1 (Vertucci type I)

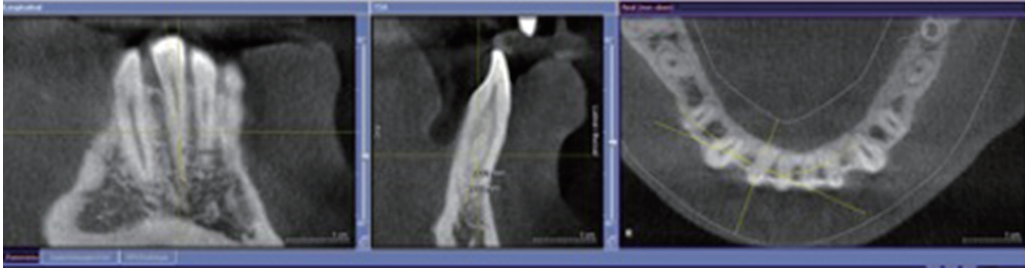


Fig. 2 Vertucci's classification type 2-1 (Vertucci type II and III)

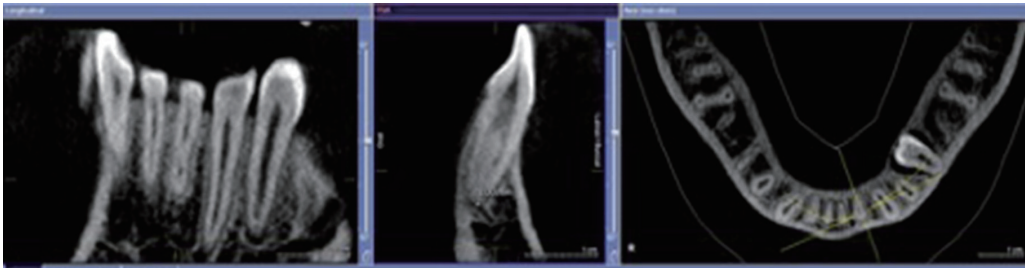


Fig. 3 Vertucci's classification type 2-2 (Vertucci type IV, VI, and VII)

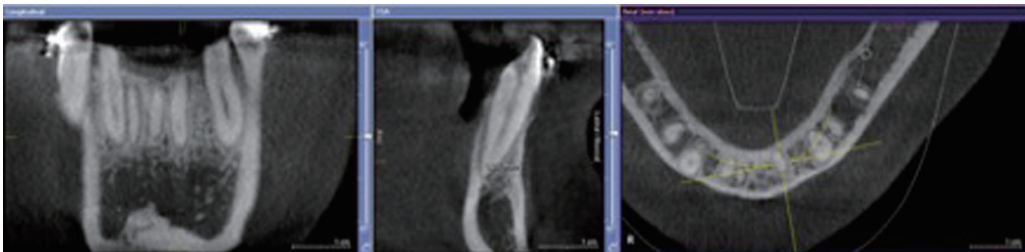


Fig. 4 Vertucci's classification type 1-2 (Vertucci type V)

- insufficient quality of CBCT scans
- no consent of patients for evaluating their images for scientific purposes

All scans were taken primarily for surgical purposes using the Galaxis Galileo (Sirona, Bensheim, Germany), which had a tube voltage of 85 kV and a tube current of 5-7 mA. The field-of-view was 15 cm<sup>3</sup> and the voxel size was 0.3 mm<sup>3</sup>.

The scans were evaluated by a trained dentist who was familiar with the evaluation of CBCT scans. All four mandibular incisors were scrolled from the crown to the apex in the mesio-distal and bucco-oral projections and in the horizontal plane. The number of root canals and root canal morphologies in all four lower anterior teeth were categorized as suggested by Vertucci [1]:

- type I (1-1): one root canal from the orifice to the apex (Fig. 1)
- type II (2-1): two root canals at the orifice fusing apically (Fig. 2)
- type III (1-2-1): one root canal at the orifice, splitting and again fusing apically
- type IV (2-2): two separate root canals from the orifice to the apex (Fig 3)
- type V (1-2): one root canal splitting into two (Fig. 4)
- type VI (2-1-2): two root canals at the orifice, joining and splitting again

- type VII (1-2-1-2): one root canal splitting, joining, and splitting again with two apical openings
- type VIII (3): three separate root canals

Data separately were collected for females and males. The patients' age was grouped as follows:

- 18-35 years, 36-45 years, 46-55 years, and >56 years.

#### Statistical analysis

The Fisher's exact test was used for all statistical analyses ( $\alpha = 0.05$ ).

#### Results

A total of 302 CBCT scans met the inclusion criteria. The mean age of patients was 44.7 (range, 18-78) years, and 116 patients were male and 186 were female (Table 1).

The central mandibular incisors had two root canals in 22.6% of patients and lateral incisors in 24.3% of the respective teeth. The type I configuration was observed in most teeth (76.4%), followed by type II (2-1) in 21.7%, and type V in 1.1%. Teeth with type IV, VI, VII, and VIII configurations were grouped together owing to their low prevalence, accounting for only 0.8% of all teeth. The type III configuration (1-2-1)

**Table 1** Age and sex of patients included in the study

Participants	Females	Males	Total
Age group (years)	<i>n</i>	<i>n</i>	<i>n</i>
18-35	54	21	75
36-45	48	39	87
46-55	42	31	73
>56	42	25	67
Total	186	116	302

**Table 3** Number and percentage of root canal configurations

Tooth	<i>n</i>	type 1-1	type 1-2	type 2-1	type 2-2
32	302	234 77.5%	2 0.7%	64 21.2%	2 0.7%
31	302	228 75.5%	3 1.0%	68 22.5%	3 1.0%
41	302	232 76.8%	4 1.3%	65 21.5%	1 0.3%
42	302	229 75.8%	4 1.3%	65 21.5%	4 1.3%
Total	1,208	923 76.4%	13 1.1%	262 21.7%	10 0.8%

was not detected in this study.

The bilateral occurrence of two root canals was detected in 17.5% of the central incisors and in 20.5% of the lateral incisors, and the total prevalence of symmetry in both the central and lateral two-canalled incisors was 12.3% (Table 2). The symmetrical occurrence of the type I configuration was 77% in the lateral and 77% for the central mandibular incisors. The type II configuration was observed in 16.6% of the central and 19.2% of the lateral incisors. The type IV configuration was not present symmetrically in the central or lateral incisors of any patient. The type V configuration appeared in symmetry in 0.3% of the central incisors and in 0.7% of the lateral incisors (Table 3).

Males (*n* = 116) showed symmetry in 18% of the central and 17.2% of the lateral incisors with respect to the prevalence of two root canals. For females (*n* = 186), the prevalence of symmetrical, two-canalled central incisors was 17.2% and that of lateral incisors was 22.6% with no significant difference compared with those in males (*P* < 0.05). Additionally, no significant influence of age was detected on symmetry regarding the number of root canals or regarding the root canal configuration (*P* < 0.05 for all). Tables 2-4 summarize these results.

**Discussion**

Many different techniques have been proposed and used for the evaluation of the internal anatomy of teeth; these techniques include the microscopic evaluation of slices, decalcification (clearing techniques), or micro-CT. In contrast to such invasive or destructive techniques, which require prior extraction of teeth, digital radiography, periapical radiography, or CBCT have been proposed for use in morphological studies. Paes da Silva Ramos Fernandes et al. investigated the root canal configuration of 40 mandibular incisors using periapical radiographs, CBCT scans generated from three scanners, and micro-CT, which was considered as the gold standard. They reported higher accuracy for all techniques for the type I and type III configurations. CBCT was clearly superior for detecting oval root canal diameters [23].

Matherne et al. demonstrated that endodontists missed one or more root canals in more than 40% of the cases when viewing radiographs. This number was definitely reduced when evaluating using CBCT images [24]. The average number of root canals of the mandibular incisors was 1.0 or 1.3 as assessed using the radiographic techniques charged coupled device and photostimulable phosphor plate, respectively, compared with 1.5 as assessed using CBCT. Prado et al. compared different techniques, such as clinical microscopic investigation, clinical observation, and the clearing of extracted teeth. They demonstrated that microscopic investigation improved the identification of second root canals in the mandibular incisors. Observations identified 1.1%, microscopy identified 5.8% and clearing identified 23.5% of the 277 mandibular incisors with two root canals. No details on symmetry, however, were reported [25]. Micro-CT, sectioning, clearing, and inspection require previous teeth extraction and are therefore not suited for clinical use. Conversely, CBCT or radiography has been used for clinically evaluating the internal anatomy. Neelakantan et al. reported high accuracy of CBCT for identifying root canal systems among different techniques for studying the root canal anatomy [15,26].

**Table 2** Prevalence of symmetry of double root canals and of symmetry based on Vertucci's classification

	Bilateral occurrence of double root canals patients ( <i>n</i> ) %	Bilateral occurrence of identical Vertucci's type patients ( <i>n</i> ) %
31/41	53 17.5%	268 89.0%
32/42	62 20.5%	277 91.7%
31/41 and 32/42	37 12.3%	

**Table 4** Prevalence of symmetry in different age groups

Age group	Symmetry of Vertucci's classification ( <i>n</i> )
	41/31 42/32
18-35	60.9% 75.0%
36-45	89.5% 82.0%
46-55	76.5% 72.0%
>56	61.1% 62.5%

In a comparative study on the root canal configuration of 122 extracted human premolars using CBCT with a voxel size of 0.08 mm<sup>3</sup> and periapical radiography with micro-CT as the gold standard, the performance of CBCT was equal to that of micro-CT and was clearly superior to that of periapical radiography [27]. Accuracy in the description of the root canal configuration was 0.55 for radiography and 0.89 for CBCT, and values for sensitivity and specificity were 0.18 and 0.79 and 0.93 and 0.98, respectively. Despite the high resolution, a number of configurations such as Vertucci types III, VII, and "others" were not detected in that study, which is consistent with the results of the present study. In this study, CBCT with a voxel size of 0.3 mm<sup>3</sup> was used; the resolution used was lower than that used by Lin et al., Kayaoglu et al. and Xu et al. for the investigation of the root canal anatomy [19,21,28]. They evaluated scans obtained from CBCT with a voxel size of 0.20, 0.16, and 0.125 mm<sup>3</sup>. This lower resolution may be associated with some drawbacks when used for endodontic diagnosis or instrumentation; nevertheless, it was still precise enough for analyzing the number and morphology of root canals of the mandibular incisors. The same voxel size of 0.3 mm<sup>3</sup> has been used in a previous study assessing the root canal morphology of anterior teeth in a Turkish population [29].

Although several other classifications have been described in the literature [30,31], in the present study, the Vertucci's classification was used as this seems to be the most frequently used classification [6,29,32-34]. Not all root canal systems identified in the three-dimensional CBCT scans can be exactly classified using this classification system [35]. Ahmed et al. recently introduced a more detailed classification based on micro-CT scans [31], which could be used in future studies.

It is well known that with increasing age, the deposition of secondary dentine results in the narrowing and calcification of root canals, which consequently impede the radiographic appearance of these structures [36-38]. It should be kept in mind that CBCT has some limitations for detecting extremely narrow root canals owing to its limited resolution [39], which may create clinical problems in assessing teeth that have suffered dental trauma or teeth in elderly people. Therefore, teeth with calcified root canals that were not visible in CBCT scans were excluded, as no evaluation was possible on the original number of root canals in these teeth. In the present study, no significant differences were detected between the different age groups in terms of the number of root canals and morphological symmetry. Moreover, the influence of sex on the prevalence of symmetries was not significant. Kayaoglu et al. reported that patients aged >56 years had fewer mandibular anterior teeth with two root canals than younger patients [19]. They also reported an influence of sex on the prevalence of two root canals in the mandibular canines but not in the incisors. The prevalence of two root canals in the mandibular incisors was significantly higher in males than in females in a Turkish population [29].

In comparative *ex-vivo* studies using extracted teeth, the external and internal anatomies should be fairly balanced between the experimental and control group[s] to avoid any anatomical bias [21,40]. In many studies, teeth were randomly assigned into groups, and other studies analyzed matched pairs, which at least showed similarity in the defined anatomical parameters. If certain tooth groups show a sufficiently high degree of symmetry, the pairs of contralateral teeth could be used for *ex-vivo* investigations, as already suggested [21].

The prevalence of the mandibular incisors with two root canals varies considerably between 11% and 68% [19]. Only a limited number of studies have investigated the symmetry in human teeth with regard to the number of root canals [15-22].

Anatomical symmetry regarding the number of root canals in the maxillary and mandibular molars was as high as 70-81% [18]. Felsypremila et al. (2015) reported a similarly high prevalence of symmetry in the maxillary first (81.5%) and second (81.5%) as well as the mandibular first (96.1%) and second premolars (98.3%) in a CBCT evaluation of posterior teeth in an Indian subpopulation. The first molars (77.5% and 82.1%) presented a higher rate of symmetry than second molars (70.8% and 78.6%). The overall percentage of symmetry in the study was 83.9% (range, 70-98%), depending on the type of tooth [20]. In a study by Johnsen et al., micro-CT was used to investigate the number, length, width and internal anatomy of root canals of 41 pairs of intact premolars extracted for orthodontic reasons [22]. Overall, a high degree of symmetry was observed, except for in the apical region (foramina, accessory canals, and isthmi), which did not show symmetrical anatomy. Xu et al. even collected 60 pairs of contralateral premolars and compared root canal type, curvature, and length along with the apical foramen. In a strict protocol using CBCT (voxel size, 0.125 mm<sup>3</sup>), only six pairs of teeth showed a degree of symmetry that was suited for comparative *ex-vivo* studies. In most of the pairs, root canal curvature was not symmetrical [21].

Kayaoglu et al. recently performed an investigation on root and root canal symmetry in mandibular anterior teeth in a Turkish subpopulation using CBCT. The symmetry in teeth with double root canals was 45% for the central and 29% for the lateral incisors, and the overall symmetry of the mandibular incisors ranged from 90-95% [19]. Lin et al. investigated the root canal morphology (number and Vertucci type of root canals) of mandibular incisors using CBCT in 353 Chinese patients. In 10.9% of the central incisors and 25.5% of the lateral incisors, a second root canal was detected. A total of 95.2% of the central incisors and 93.8% of the lateral incisors showed symmetry regarding the number of root canals, and 92.7% and 89.2%, respectively, showed symmetry regarding canal configuration [28].

A high overall prevalence of symmetry regarding root canal number to some extent is owing to the fact that the majority of mandibular incisors had only one root canal. Interestingly, however, the prevalence of symmetry regarding root canal number and configuration for incisors with two root canals was only moderate. Clinically, this implies that, in cases in which a one two-canal incisor has been detected and treated, the contralateral incisor with only moderate probability will also have two root canals with an identical or at least similar configuration.

It can be concluded that the internal anatomy of a mandibular incisor cannot be exactly predicted from the root canal anatomy of the contralateral tooth as the prevalence of symmetry regarding root canal number and configuration is only moderate. Thorough individual clinical and radiographic inspection of each mandibular incisor still remains mandatory. Considering three-dimensional CBCT for diagnostic reasons before performing root canal treatment in the mandibular incisors is helpful to ensure treatment of all root canals.

For *ex-vivo* studies using the extracted mandibular incisors, using the contralateral incisors does not necessarily guarantee sufficient matching in terms of root canal number and configuration.

## Acknowledgments

The authors acknowledge support by Open Access Publication funds of the University of Göttingen.

## Conflict of interest

None.

## References

- Vertucci FJ (1984) Root canal anatomy of the human permanent teeth. *Oral Surg Oral Med Oral Pathol* 58, 589-599.
- Green D (1973) Double canals in single roots. *Oral Surg Oral Med Oral Pathol* 35, 689-696.
- Miyashita M, Kasahara E, Yasuda E, Yamamoto A, Sekizawa T (1997) Root canal system of the mandibular incisor. *J Endod* 23, 479-484.
- Madeira MC, Hetem S (1973) Incidence of bifurcations in mandibular incisors. *Oral Surg Oral Med Oral Pathol* 36, 589-591.
- Kartal N, Yanikoğlu FC (1992) Root canal morphology of mandibular incisors. *J Endod* 18,

- 562-564.
- Sert S, Aslanalp V, Tanalp J (2004) Investigation of the root canal configurations of mandibular permanent teeth in the Turkish population. *Int Endod J* 37, 494-499.
- Allen RK, Newton CW, Brown CE (1989) A statistical analysis of surgical and nonsurgical endodontic retreatment cases. *J Endod* 15, 261-266.
- Hoen MM, Pink FE (2002) Contemporary endodontic retreatments: an analysis based on clinical treatment findings. *J Endod* 28, 834-836.
- Wolcott J, Ishley D, Kennedy W, Johnson S, Minnich S (2002) Clinical investigation of second mesiobuccal canals in endodontically treated and retreated maxillary molars. *J Endod* 28, 477-479.
- Wolcott J, Ishley D, Kennedy W, Johnson S, Minnich S, Meyers J (2005) A 5 yr clinical investigation of second mesiobuccal canals in endodontically treated and retreated maxillary molars. *J Endod* 31, 262-264.
- Mauger MJ, Waite RM, Alexander JB, Schindler WG (1999) Ideal endodontic access in mandibular incisors. *J Endod* 25, 206-207.
- Logani A, Singh A, Singla M, Shah N (2009) Labial access opening in mandibular anterior teeth—an alternative approach to success. *Quintessence Int* 40, 597-602.
- Klein RM, Blake SA, Nattress BR, Hirschmann PN (1997) Evaluation of X-ray beam angulation for successful twin canal identification in mandibular incisors. *Int Endod J* 30, 58-63.
- Monsarrat P, Arcaute B, Peters OA, Maury E, Telmon N, Georgelin-Gurgel M et al. (2016) Interrelationships in the variability of root canal anatomy among the permanent teeth: a full-mouth approach by cone-beam CT. *PLoS One* 11, e0165329.
- Neelakantan P, Subbarao C, Subbarao CV, Ravindranath M (2010) Root and canal morphology of mandibular second molars in an Indian population. *J Endod* 36, 1319-1322.
- Zhang R, Yang H, Yu X, Wang H, Hu T, Dummer PMH (2011) Use of CBCT to identify the morphology of maxillary permanent molar teeth in a Chinese subpopulation. *Int Endod J* 44, 162-169.
- Tian YY, Guo B, Zhang R, Yu X, Wang H, Hu T et al. (2012) Root and canal morphology of maxillary first premolars in a Chinese subpopulation evaluated using cone-beam computed tomography. *Int Endod J* 45, 996-1003.
- Plotino G, Tucci L, Grande NM, Testarelli L, Messineo D, Ciotti M et al. (2013) Symmetry of root and root canal morphology of maxillary and mandibular molars in a white population: a cone-beam computed tomography study in vivo. *J Endod* 39, 1545-1548.
- Kayaoglu G, Peker I, Gumusok M, Sarikir C, Kayadugun A, Ucoo O (2015) Root and canal symmetry in the mandibular anterior teeth of patients attending a dental clinic: CBCT study. *Braz Oral Res*, doi: 10.1590/1807-3107BOR-2015.vol29.0090.
- Felsypremila G, Vinothkumar TS, Kandaswamy D (2015) Anatomical symmetry of root and root canal morphology of posterior teeth in Indian subpopulation using cone beam computed tomography: a retrospective study. *Eur J Dent* 9, 500-507.
- Xu J, Shao MY, Pan HY, Lei L, Liu T, Cheng L et al. (2016) A proposal for using contralateral teeth to provide well-balanced experimental groups for endodontic studies. *Int Endod J* 49, 1001-1008.
- Johnsen GF, Dara S, Asjad S, Sunde PT, Haugen HJ (2017) Anatomic comparison of contralateral premolars. *J Endod* 43, 956-963.
- Paes da Silva Ramos Fernandes LM, Rice D, Ordinola-Zapata R, Alvares Capelozza AL, Bramante CM, Jaramillo D et al. (2014) Detection of various anatomic patterns of root canals in mandibular incisors using digital periapical radiography, 3 cone-beam computed tomographic scanners, and micro-computed tomographic imaging. *J Endod* 40, 42-45.
- Matherne RP, Angelopoulos C, Kulild JC, Tira D (2008) Use of cone-beam computed tomography to identify root canal systems in vitro. *J Endod* 34, 87-89.
- Prado MC, Gusman H, Belladonna FG, Prado M, Ormiga F (2016) Effectiveness of three methods for evaluating root canal anatomy of mandibular incisors. *J Oral Sci* 58, 347-351.
- Neelakantan P, Subbarao C, Subbarao CV (2010) Comparative evaluation of modified canal staining and clearing technique, cone-beam computed tomography, peripheral quantitative computed tomography, spiral computed tomography, and plain and contrast medium-enhanced digital radiography in studying root canal morphology. *J Endod* 36, 547-551.
- Sousa TO, Haiter-Neto F, Nascimento EHL, Peroni LV, Freitas DQ, Hassan B (2017) Diagnostic accuracy of periapical radiography and cone-beam computed tomography in identifying root canal configuration of human premolars. *J Endod* 43, 1176-1179.
- Lin Z, Hu Q, Wang T, Ge J, Liu S, Zhu M et al. (2014) Use of CBCT to investigate the root canal morphology of mandibular incisors. *Surg Radiol Anat* 36, 877-882.
- Altunsoy M, Ok E, Nur BG, Aglarci OS, Gungor E, Colak M (2014) A cone-beam computed tomography study of the root canal morphology of anterior teeth in a Turkish population. *Eur J Dent* 8, 302-306.
- Ng YL, Aung TH, Alavi A, Gulabivala K (2001) Root and canal morphology of Burmese maxillary molars. *Int Endod J* 34, 620-630.
- Ahmed HMA, Versiani MA, De-Deus G, Dummer PMH (2017) A new system for classifying root and root canal morphology. *Int Endod J* 50, 761-770.
- Calışkan MK, Pehlivan Y, Sepetçioğlu F, Türkün M, Tuncer SS (1995) Root canal morphology of human permanent teeth in a Turkish population. *J Endod* 21, 200-204.
- Sert S, Bayirli GS (2004) Evaluation of the root canal configurations of the mandibular and maxillary permanent teeth by gender in the Turkish population. *J Endod* 30, 391-398.
- Al-Qudah AA, Awawdeh LA (2006) Root canal morphology of mandibular incisors in a Jordanian population. *Int Endod J* 39, 873-877.
- Filpo-Perez C, Bramante CM, Villas-Boas MH, Húngaro Duarte MA, Versiani MA, Ordinola-Zapata R (2015) Micro-computed tomographic analysis of the root canal morphology of the distal root of mandibular first molar. *J Endod* 41, 231-236.
- Nitzan DW, Michaeli Y, Weinreb M, Azaz B (1986) The effect of aging on tooth morphology: a study on impacted teeth. *Oral Surg Oral Med Oral Pathol* 61, 54-60.
- Woods MA, Robinson QC, Harris EF (1990) Age-progressive changes in pulp widths and root lengths during adulthood: a study of American blacks and whites. *Gerodontology* 9, 41-50.
- Thomas RP, Moule AJ, Bryant R (1993) Root canal morphology of maxillary permanent first molar teeth at various ages. *Int Endod J* 26, 257-267.
- Baratto Filho F, Zaitter S, Haragushiku GA, de Campos EA, Abuabara A, Correr GM (2009) Analysis of the internal anatomy of maxillary first molars by using different methods. *J Endod* 35, 337-342.
- Hülsmann M (2013) Research that matters - canal preparation, retreatment and working length studies. *Int Endod J* 46, 293-295.