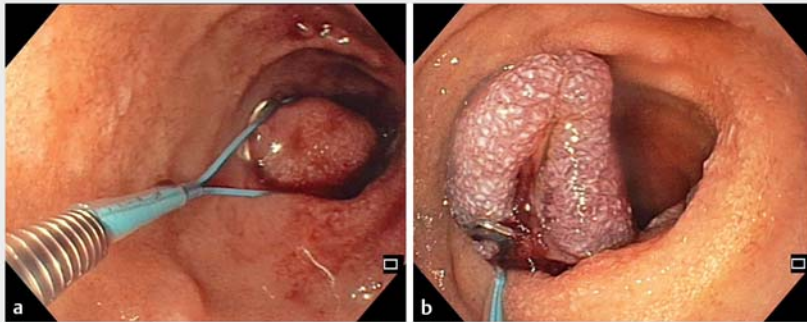
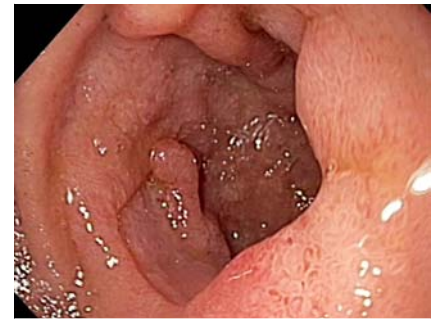

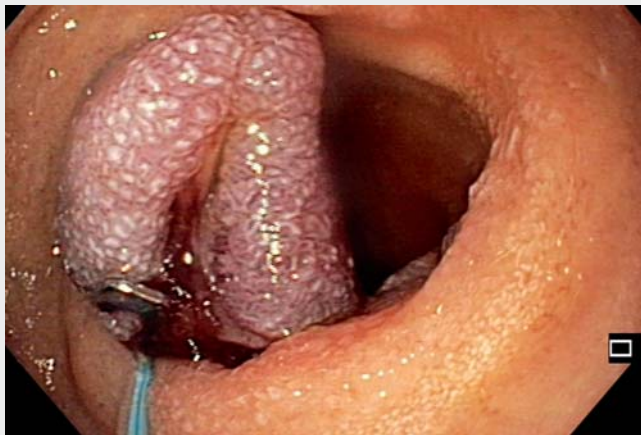## Endoloop rescue therapy for a duodenal ulcer that re-bled under the clip base after application of an 11/3 traumatic over-the-scope clip



► **Fig. 1** Endoscopic views showing a duodenal ulcer that had re-bled following previous application of an over-the-scope clip: **a** being treated endoscopically with an endoloop; **b** after successful treatment with the endoloop.



► **Fig. 2** Follow-up endoscopic view after 6 weeks showing a clean ulcer base, with no signs of bleeding. The over-the-scope clip and endoloop had both fallen off.



► **Video 1** Duodenal ulcer that was re-bleeding from under the clip base after application of a 11/3 traumatic over-the-scope clip (OTSC). An endoloop was applied as endoscopic rescue therapy when the OTSC failed to control bleeding.

A 67-year-old patient with melena and symptoms of shock, along with additional clinical symptoms of fatigue and severe anemia (initial hemoglobin level 7.9 g/dL), was transferred to our intensive care unit. The patient had multiple comorbidities with chronic renal failure, cardiac decompensation, peripheral arterial occlusive disease, and chronic obstructive pulmonary disease. Additionally, he had had a recent arterial embolus

and, for this reason, was anticoagulated with heparin. A gastroscopy was performed 3 days after the patient had started anticoagulation therapy, when he presented with clinical signs of gastrointestinal bleeding. A Forrest IIa ulcer was seen in the descending duodenum and, because of the anticoagulation, definitive hemostasis was needed, being achieved following application of an 11/3 traumatic over-the-scope clip (OTSC; Ovesco,

Tübingen, Germany). The patient's clinical course remained stable for the first 9 days. Unfortunately, on postoperative day 9, his physical condition progressively worsened with severe gastrointestinal bleeding, tachycardia, and hypotension, despite endoscopic intervention and transfusion of numerous red blood cell units ( $n=8$ ).

We decided to repeat a gastroscopy and found an active site of bleeding (Forrest Ib) under the OTSC, probably originating from the arteria gastroduodenalis. We assumed the OTSC had been wrongly positioned during the initial application with insufficient compression of the target vessel. Owing to our hypothesis of insufficient vessel compression, we decided to apply an endoloop (MAJ254; Olympus) under the OTSC in order to achieve sufficient compression of the vessel (► **Fig. 1**; ► **Video 1**).

The further clinical course was uneventful and the patient rapidly recovered without restrictions. In keeping with the clinical picture, an endoscopic follow-up examination after 6 weeks showed persistent hemostasis with a healed ulcer. The OTSC and endoloop had both fallen off (► **Fig. 2**).

In conclusion, it has been shown that the OTSC is a safe hemostatic tool [1,2]; however, our case shows that precise

placement of the OTSC plastic cap is essential to achieve sufficient hemostasis. If misplacement occurs, re-bleeding after OTSC application can appear and treatment options have so far been limited, with possible options being fibrin glue injection, radiologic embolization, or surgery [3]. To the best of our knowledge, this case provides the first evidence that the application of an endoloop after re-bleeding under an OTSC is technically safe and could be an alternative endoscopic rescue option.

Endoscopy\_UCTN\_Code\_TTT\_1AO\_2AN

### Competing interests

The authors declare that they have no conflict of interest.

### The authors

**Carlo Jung<sup>1</sup>, Adrien Sportes<sup>2</sup>, Volker Ellenrieder<sup>1</sup>, Edris Wedi<sup>1</sup>**

- 1 Department of Gastroenterology and Gastrointestinal Oncology, Center of Interdisciplinary Endoscopy, University Medical Center Göttingen, Göttingen, Germany
- 2 Institut Arnault TZANCK Gastroenterology Unit, Saint-Laurent-du-Var, France

### Corresponding author

**Edris Wedi, MD**

Department of Gastroenterology and Gastrointestinal Oncology, Center of Interdisciplinary Endoscopy, University Medical Center Göttingen, Georg-August-University, D-37075 Göttingen, Germany  
edris1@web.de

### References

- [1] Chandrasekar VT, Desai M, Aziz M et al. Efficacy and safety of over-the-scope clips for gastrointestinal bleeding: a systematic review and meta-analysis. *Endoscopy* 2019; 51: 941–949
- [2] Wedi E, Fischer A, Hochberger J et al. Multi-center evaluation of first-line endoscopic treatment with the OTSC in acute non-variceal upper gastrointestinal bleeding and comparison with the Rockall cohort: the FLETRock study. *Surg Endosc* 2018; 32: 307–314
- [3] Schmidt A, Golder S, Goetz M et al. Over-the-scope clips are more effective than standard endoscopic therapy for patients with recurrent bleeding of peptic ulcers. *Gastroenterology* 2018; 155: 674–686 e676

### Bibliography

DOI <https://doi.org/10.1055/a-1089-7580>  
Published online: 29.1.2020  
*Endoscopy* 2020; 52: E253–E254  
© Georg Thieme Verlag KG  
Stuttgart · New York  
ISSN 0013-726X

#### ENDOSCOPY E-VIDEOS <https://eref.thieme.de/e-videos>



*Endoscopy E-Videos* is a free access online section, reporting on interesting cases and new

techniques in gastroenterological endoscopy. All papers include a high quality video and all contributions are freely accessible online.

This section has its own submission website at  
<https://mc.manuscriptcentral.com/e-videos>