

Katharina Stoeck, MD\*  
Per-Ole Carstens, MD\*  
Sven Jarius, MD  
Dirk Raddatz, MD  
Winfried Stöcker, MD  
Brigitte Wildemann, MD  
Jens Schmidt, MD

*Neurol Neuroimmunol  
Neuroinflamm*  
2015;2:e86; doi: 10.1212/  
NXI.0000000000000086

## PREDNISOLONE AND AZATHIOPRINE ARE EFFECTIVE IN DPPX ANTIBODY-POSITIVE AUTOIMMUNE ENCEPHALITIS

### OPEN

Antibodies to dipeptidyl-peptidase-like protein-6 (DPPX-Ab), a subunit of the Kv4.2 potassium channel, have recently been described in patients with encephalitis.<sup>1</sup> DPPX-Ab are part of an expanding spectrum of autoantibodies to CNS cell surface molecules.<sup>2–4</sup> So far, only a few patients with DPPX-Ab have been reported in the literature, and little is known about treatment responses.

**Case report.** A 40-year old woman presented with an unsteady gait, ataxia of the arms, a whole-body tremor, memory deficits, and panic attacks lasting for 1.5 years. She experienced a severe weight loss of around 80 kg (previous weight ~160 kg) and had night sweats and diarrhea that preceded the neurologic symptoms. Her symptoms led to social withdrawal, inability to continue her work as a retail saleswoman, and need for help with daily care. Institutional review board–approved informed consent was obtained to use clinical and laboratory data in this report.

On admission, the patient was fully oriented and displayed psychomotor slowing and an impaired short-term memory. She scored 27/30 points on the Mini-Mental State Examination. More detailed testing revealed deficits in attention, executive functions, figural memory, and verbal learning, consistent with mild cognitive impairment.

Saccadic pursuit gaze movements were noted in all directions, as were tremors of the voice, body, and limbs. She displayed a severe acoustic startle response. There was no paresis; all reflexes were brisk and pyramidal signs were positive. Hypesthesia was noted in both legs. The patient displayed severe ataxia when sitting or standing. The maximal walking distance was 500 meters; she walked 200 meters on the 3-minute walk test (3MWT). The timed up and go test (TUG) took 9.8 seconds.

EEG was normal. Nerve conduction studies displayed a demyelinating sensorimotor polyneuropathy. Motor evoked potentials of the lower limbs showed prolonged central motor conduction times for both legs and normal peripheral latencies, consistent with a

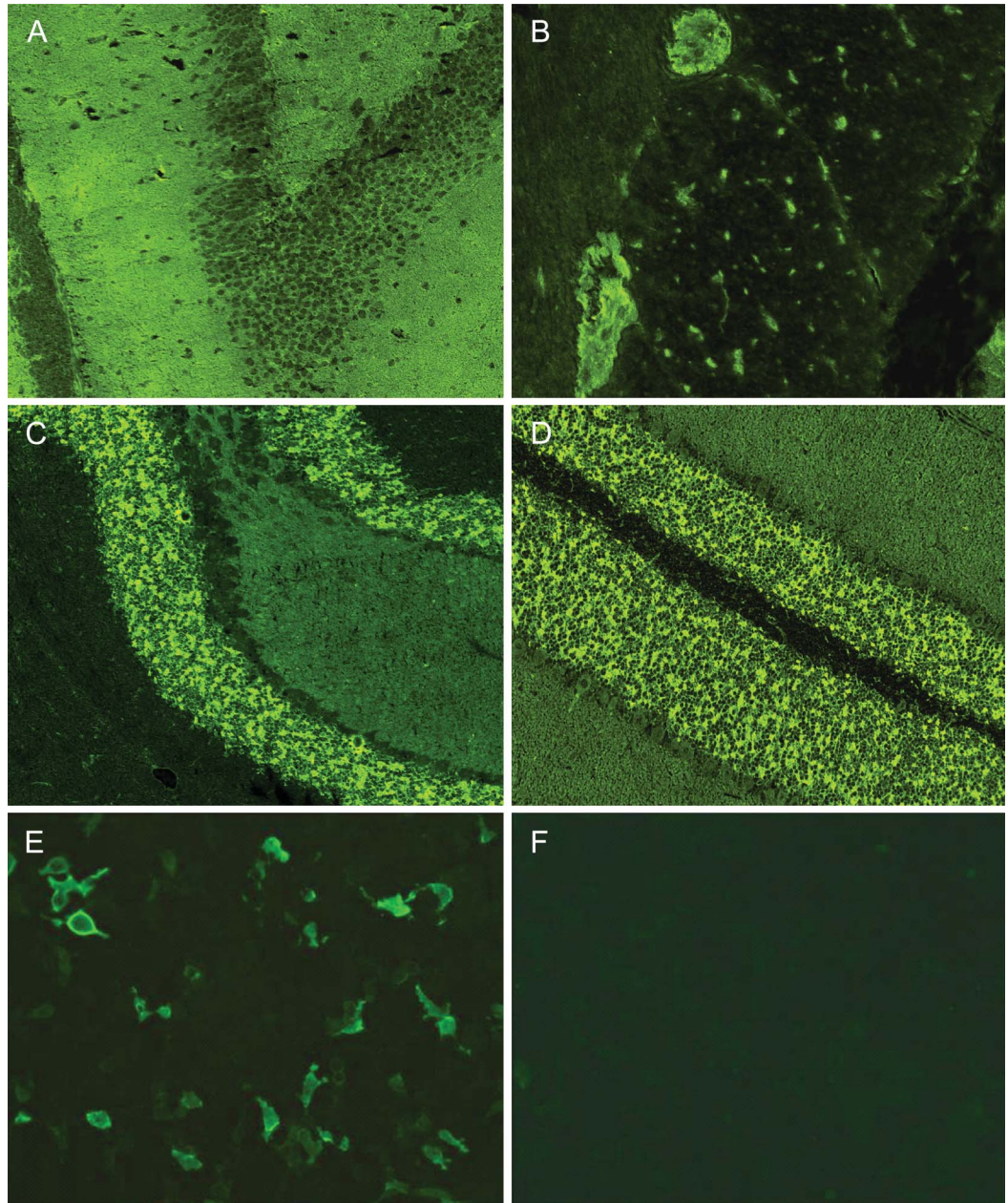
central lesion due to the encephalitis. Somatosensory evoked potentials were also impaired, but discrimination between a peripheral and central lesion was not possible. CSF was normal, with no evidence of intrathecal immunoglobulin G (IgG) synthesis. S100 protein was elevated in CSF (3.4  $\mu\text{g/L}$ ; normal <2.7  $\mu\text{g/L}$ ); tau, phosphorylated tau, and  $\beta$ -amyloid were normal. Brain MRI was normal initially and 6 months later.

A whole-body CT scan displayed bilateral adrenal masses without significant changes over 6 months. MRI suggested adrenal adenomas, which were excluded by an endosonographically guided biopsy. Clinical or laboratory signs of hormone excess were absent. <sup>18</sup>F-fluorodeoxyglucose (FDG)-PET CT showed increased activity in the gastric wall and duodenum. Biopsies from these regions revealed nonspecific inflammatory changes but no tumor.

Routine workup of blood was normal. A highly positive IgG serum titer of autoantibodies against DPPX (1/10,000) was noted. Immunostaining demonstrated typical patterns on DPPX-transfected cells and tissue sections of hippocampus, cerebellum, and primate myenteric plexus (figure). Tests for other antibodies associated with tumors or autoimmune inflammatory disorders were negative.

The patient received 1 g IV methylprednisolone per day for 3 days, followed by 80 mg prednisolone orally. At follow-up after 6 weeks, all neurologic symptoms and cognition had substantially improved, including psychomotor slowing, short-term memory, tremor, ataxia, reflexes, hypesthesia, pyramidal signs, ocular motor function, and startle response. After 3 months, all of these symptoms had completely resolved, except a very slight gait ataxia during the heel-to-toe test with closed eyes. In line with improved neurologic examination, walking tests showed a maximum distance of 1,500 meters, a 3MWT distance of 260 meters, and a TUG of 7.4 seconds. Nerve conduction had recovered completely. Repeat CT scans after 3 and 6 months did not show a tumor.

Prednisolone was slowly tapered over 6 months to 5 mg daily as follows: 80 mg/day for 4 weeks; 1 week each at 70 mg, 60 mg, 50 mg, and 40 mg; 1 month each at 30 mg and 20 mg; and 2 weeks each at 17.5 mg, 15 mg, 12.5 mg, 10 mg, and 7.5 mg. After 8 weeks of prednisolone treatment (dosed at 40 mg/day),



Immunohistochemistry displayed binding of the patient's serum immunoglobulin G (IgG) to rat hippocampus (A), primate myenteric plexus (B), and mouse (C) and primate (D) cerebellum tissue sections in a staining pattern compatible with dipeptidyl-peptidase-like protein-6 (DPPX) antibodies. Specificity for DPPX was confirmed in a cell-based assay by binding of the patient's IgG to HEK293 cells transfected with human DPPX (E) but not to mock-transfected cells (F). IgG was detected using a fluorescein isothiocyanate-conjugated antibody from goat (green).

azathioprine was initiated at 50 mg/day. Over 8 weeks, azathioprine was gradually increased to 300 mg/day and achieved appropriate lymphocyte suppression. Within 6 months, the DPPX-IgG titer markedly declined to 1/1,000 in serum and 1/320 in CSF. The patient remained clinically stable over 18 months. Her body weight increased to 98 kg over 6 months and remained stable thereafter.

**Discussion.** Thus far, 27 cases of autoimmune encephalitis associated with DPPX-Ab have been reported. In

these patients, a clinical phenotype similar to that of our patient was present, including a prominent startle reflex and neuropsychiatric symptoms.<sup>1,5,6</sup>

DPPX has been demonstrated to be expressed in the gastrointestinal tract,<sup>1</sup> suggesting that the patient's diarrhea might be explained by an autoimmune reaction in the gut. Gastrointestinal symptoms were also present in 13/27 previously reported patients with DPPX-Ab. Of note, the increased activity in the gastric wall and duodenum as revealed by <sup>18</sup>F-FDG-PET CT

scan in our patient might have reflected such underlying inflammation; this presumption is corroborated by inflammatory changes on gastric biopsies.

Most patients described so far experienced an initial benefit from glucocorticosteroids but subsequently relapsed, e.g., during dose tapering. Six of 7 patients required prolonged immunotherapy including high-dose IVIg, plasma exchange, rituximab, or cyclophosphamide. Our patient clearly and persistently improved after treatment with prednisolone together with azathioprine. Such early add-on immunosuppression is well-established in the treatment of other autoimmune neurologic disorders such as neuromyelitis optica<sup>7</sup> or cerebral vasculitis.<sup>8</sup> In neuromyelitis optica, rituximab has been shown to be very effective. However, this drug can cause progressive multifocal leukoencephalopathy. In cerebral vasculitis, treatment is usually initiated with pulsed cyclophosphamide and tapered down to a milder immunosuppressant such as azathioprine. Cyclophosphamide is a toxic chemotherapy drug that may cause several side effects, including hematologic malignancies. Therefore, we suggest that patients with DPPX-Ab-positive encephalitis initially receive immunosuppression by glucocorticosteroids alone, and if they respond, moderate immunosuppression by azathioprine be added during tapering of the glucocorticosteroid. A clinical trial for this disease is highly desirable but difficult to accomplish due to its rarity.

*\*These authors contributed equally to the manuscript.*

*From the Clinic for Neurology (K.S., P.-O.C., J.S.), Division of Gastroenterology and Endocrinology (D.R.), Department of Internal Medicine, and Department of Neuroimmunology (J.S.), Institute for Multiple Sclerosis Research and Hertie Foundation, University Medical Center Göttingen, Germany; Molecular Neuroimmunology (S.J., B.W.), Department of Neurology, University of Heidelberg, Germany; and Institute of Experimental Immunology (W.S.), Euroimmun AG, Lübeck, Germany.*

*Author contributions: Planning of the study: K.S., B.W., J.S. Acquisition of data: K.S., P.-O.C., S.J., D.R., W.S. Analysis of the data: P.-O.C., S.J., B.W., J.S. Drafting the manuscript: K.S., S.J., J.S. Critical review of the manuscript: K.S., P.-O.C., S.J., D.R., W.S., B.W., J.S.*

*Study funding: No targeted funding reported.*

*Disclosure: K. Stoeck reports no disclosures. P.-O. Carstens has received travel funding from CSL Behring, VitalAire, and Grifols. S. Jarius and D. Raddatz report no disclosures. W. Stöcker holds patents for Kalibrationsstreifen für einen Immunoblot., Vorrichtung und Verfahren zur automatischen Fokussierung für die Mikroskopie schwach leuchtender Substrate, Verfahren zum spezifischen und quantitativen Nachweis von Antikörpern in einer Probe, Verfahren zum Nachweis von Anti-NMDA-Rezeptor-Autoantikörpern zum Einsatz in Diagnoseverfahren, Verfahren und Vorrichtung zur Bearbeitung von Proben biologischen Materials, Diagnosekit sowie*

*Verfahren zur Untersuchung einer menschlichen Patientenprobe auf das Vorhandensein Neuromyelitis-optica-spezifischen Antikörpern, Vorrichtung zur Steuerung einer Pipettiervorrichtung, Verfahren und Analysevorrichtung zur mikroskopischen Untersuchung eines Gewebeschnittes oder eines Zellausstriches, and Verfahren sowie Vorrichtung zur Inkubation von Patiententesten and is employed by and holds stock in Euroimmun Medizinische Labordiagnostika HG. B. Wildemann has served on the scientific advisory board for Novartis; received travel funding and speaker honoraria from Bayer Healthcare, Biogen Idec, Merck Serono, Genzyme, a Sanofi Company, Novartis Pharmaceuticals, and Teva Pharma; and has received research support from Biogen Idec, Biotest, Merck Serono, Novartis Pharmaceuticals, Teva Pharma, The Dietmar-Hopp Foundation, and German Ministry of Education and Research. J. Schmidt has received travel funding from Biogen, Biotest, CSL Behring, Grifols, Novartis, Octapharma, and VitalAire; is on the editorial board for BMC Neurology, American Journal of Neuroscience, Edorium Journal of Neurology, World Journal of Neurology, Journal of Neuromuscular Diseases, and Edorium Journals; has consulted for Novartis; and received research support from CSL Behring, Novartis, and Octapharma. Go to [Neurology.org/nn](http://Neurology.org/nn) for full disclosure forms. The Article Processing Charge was paid by University Medical Center Göttingen, Germany.*

*This is an open access article distributed under the terms of the Creative Commons Attribution-Noncommercial No Derivative 3.0 License, which permits downloading and sharing the work provided it is properly cited. The work cannot be changed in any way or used commercially.*

*Received November 20, 2014. Accepted in final form January 16, 2015.*

*Correspondence to Dr. Schmidt: [j.schmidt@gmx.org](mailto:j.schmidt@gmx.org)*

1. Boronat A, Gelfand JM, Gresa-Arribas N, et al. Encephalitis and antibodies to dipeptidyl-peptidase-like protein-6, a subunit of Kv4.2 potassium channels. *Ann Neurol* 2013;73:120–128.
2. Leypoldt F, Armangue T, Dalmau J. Autoimmune encephalopathies. *Ann N Y Acad Sci Epub* 2014 Oct 14. doi: 10.1111/nyas.12553.
3. Armangue T, Leypoldt F, Dalmau J. Autoimmune encephalitis as differential diagnosis of infectious encephalitis. *Curr Opin Neurol* 2014;27:361–368.
4. Wildemann B, Jarius S. The expanding range of autoimmune disorders of the nervous system. *Lancet Neurol* 2013;12:22–24.
5. Balint B, Jarius S, Nagel S, et al. Progressive encephalomyelitis with rigidity and myoclonus: a new variant with DPPX antibodies. *Neurology* 2014;82:1521–1528.
6. Tobin WO, Lennon VA, Komorowski L, et al. DPPX potassium channel antibody: frequency, clinical accompaniments, and outcomes in 20 patients. *Neurology* 2014;83:1797–1803.
7. Jarius S, Wildemann B, Paul F. Neuromyelitis optica: clinical features, immunopathogenesis and treatment. *Clin Exp Immunol* 2014;176:149–164.
8. Salvarani C, Brown RD Jr, Hunder GG. Adult primary central nervous system vasculitis: an update. *Curr Opin Rheumatol* 2012;24:46–52.

# Neurology<sup>®</sup> Neuroimmunology & Neuroinflammation

## **Prednisolone and azathioprine are effective in DPPX antibody–positive autoimmune encephalitis**

Katharina Stoeck, Per-Ole Carstens, Sven Jarius, et al.  
*Neurol Neuroimmunol Neuroinflamm* 2015;2;  
DOI 10.1212/NXI.0000000000000086

**This information is current as of March 12, 2015**

<b>Updated Information &amp; Services</b>	including high resolution figures, can be found at: <a href="http://nn.neurology.org/content/2/3/e86.full.html">http://nn.neurology.org/content/2/3/e86.full.html</a>
<b>References</b>	This article cites 7 articles, 0 of which you can access for free at: <a href="http://nn.neurology.org/content/2/3/e86.full.html#ref-list-1">http://nn.neurology.org/content/2/3/e86.full.html#ref-list-1</a>
<b>Subspecialty Collections</b>	This article, along with others on similar topics, appears in the following collection(s): <b>Autoimmune diseases</b> <a href="http://nn.neurology.org/cgi/collection/autoimmune_diseases">http://nn.neurology.org/cgi/collection/autoimmune_diseases</a>
<b>Permissions &amp; Licensing</b>	Information about reproducing this article in parts (figures, tables) or in its entirety can be found online at: <a href="http://nn.neurology.org/misc/about.xhtml#permissions">http://nn.neurology.org/misc/about.xhtml#permissions</a>
<b>Reprints</b>	Information about ordering reprints can be found online: <a href="http://nn.neurology.org/misc/addir.xhtml#reprintsus">http://nn.neurology.org/misc/addir.xhtml#reprintsus</a>

*Neurol Neuroimmunol Neuroinflamm* is an official journal of the American Academy of Neurology. Published since April 2014, it is an open-access, online-only, continuous publication journal. Copyright © 2015 American Academy of Neurology. All rights reserved. Online ISSN: 2332-7812.

